***Dear Plabber,***

- This first ever System Wise 1700 document was created thanks to 3 months of daily hard work by the PLAB Skype group 'Unity' which was brought together by Dr Susmita Chowdhury.

*The team members were:*

- 🕮 **Susmita** (Lead/most ignorant as she is working full time in public health for 13 years)
- 🕮 **Asad** (Invaluable in IT and all types of support/the heart of the group)
- 🕮 **Manu** (Volunteered to solve more questions/pathologist/amazing genuine person)
- 🕮 **Saima** (Most concise clear notes/ photographic memory)
- 🕮 **Zohaib** (Great research/a surgeon)
- 🕮 **Savia** (Great research/multi-tasker with two little ones)
- 🕮 **Shanu** (Very helpful after her March exam for those appearing in June)
- 🕮 **Mona** (Great contributor in discussions)
- 🕮 **Manisha** (Gyne/great discussion contributor)
- 🕮 **Sitara** (Good discussion contributor)
- 🕮 **Samreena** (Stayed a shorter time but great)
- 🕮 **Sami** (Contributed the most early on but too brilliant for the group/still great friends)
- 🕮 **Komal** (Knowledgeable sweet supportive girl)

- The main purpose was to break down the 1700 Q Bank System wise.

- We did our own reliable research for the options (OHCM/Patient info etc.) and concluded these keys below on skype. This can save you 100s of hours of research. But I suggest you also do your own.

- 90% of the document consists of Unity research. We also added information from other circulating documents and they are referenced as Dr Khalid/Dr Rabia (and her Team).

- However, several keys may be 'incorrect' and so please use your own judgment as we take no responsibility. I suggest cross checking with Dr Khalid's latest keys (a few of which are still debatable). Finally decide on your own key.

- Sorry if some members failed to make their answers thorough. The highlights are mostly as per what the team members wanted to highlight. Blank tables to be ignored.

- Note that some 1700 Questions are *missing* from here (when members did not do their share). Questions may not be in order due to merging of documents and there is excess information than required. Read as much as needed.

- This has been circulated by our team as a generous contribution to the Plabbers' success and must not be 'sold'.

| | |
|---|---|
| **Q:414** | A 70yo man had a right hemicolectomy for ceacal carcinoma 6days ago. He now has abdominal distention and recurrent vomiting. He has not opened his bowels since surgery. There are no bowel sounds. WBC=9, Temp=37.3C. What is the single most appropriate next management?<br>a. Antibiotic therapy IV<br>b. Glycerine suppository<br>c. Laparotomy (48 hours of no bowl sound/ WBC count rising> peritonitis)<br>d. NG tube suction and IV fluids<br>e. TPN |
| | |
| **Clincher(s)** | **Hemicolectomy 6 days ago, abd distention, recurrent vomiting, bowels not open since surgery, no bowel sounds and normal temperature.** |
| A | The main manifestations of peritonitis are acute abdominal pain, abdominal tenderness and abdominal guarding,high temperature and no urine output. |
| B | An ileus patient might be given medication, including pills (laxatives), suppositories, or enemas to stimulate a bowel movement , but it's not first line. |
| C | exploratory laparotomy is carried out both to diagnose the condition and to perform therapeutic procedure. It can be done here but not as first line as no signs of perforation or evisceration etc. |
| D | **Patient should be on IV fluids to avoid Aggravating the illness symptoms.** (to relieve bowls from distention/gas- giving rest to bowel- prevents aspiration pneumonia) |
| E | **TPN (total perenteral nutrition) is is the last resort which is not the case here as we will try the first line treatment.** |
| **Key** | **D (diagnosis is paralytic ileus)** |
| Additional Information | **Paralytic ileus (paralysis of whole colon) describes the condition in which the bowel ceases to function and there is no peristalsis. Can occur due to abd surgery, pancreatitis, spinal injury or electrolyte imbalances etc.**<br><br>**Intestinal pseudo-obstruction is also called Ogilvie's syndrome. It results from massive dilatation of the colon but possibly small intestine too. It may occur in association with a number of medical conditions including:[5]**<br><br>**Chest infection**<br><br>**Acute myocardial infarction**<br><br>**Stroke**<br><br>**Acute kidney injury**<br><br>**Puerperium**<br><br>**Trauma** |

| | |
|---|---|
| | **Severe hypothyroidism**<br><br>**Electrolyte disturbance**<br><br>**spinal cord injury, those with injury above thoracic vertebrae 5 (T5) will have hypomotility problems within the bowel**<br><br>**Symptoms of illeus are: moderate, diffuse abdominal discomfort, constipation, abdominal distension, nausea/vomiting, especially after meals, vomiting of biliary fluid , lack of bowel movement and/or flatulence, excessive belching.**<br><br>• **those with injury above thoracic vertebrae 5 (T5) will have hypomotility problems within the bowel**<br><br>**Another main point to differentiate mechanical obstruction from paralytic illeus is the absence of pain and bowel sounds in paralytic illeus whereas . Opposite will be true for mechanical obstruction where an active tinkling bowel sounds can be heard and presents mainly with colicky pain.**<br><br>*Skype discussion: In (mechanical) intestinal obstruction, bowel sounds are more exaggerated (trying to push forward), but after wards, the bowel sounds reduce and die off.*<br><br>*In paralytic: completely paralysed* |
| **Reference** | Ohcm page 612 and patient info |

| | |
|---|---|
| **Q:427** | A 63yo lady with a BMI=32 comes to the ED with complaints of pigmentation on her legs. Exam: dilated veins could be seen on the lateral side of her ankle. Which of the following is involved?<br>a. Short saphenous vein<br>b. Long saphenous vein<br>c. Deep venous system<br>d. Popliteal veins<br>e. Saphano-femoral junct |
| | |
| **Clincher(s)** | **Dilated veins on the left side** |

| | |
|---|---|
| A | The small saphenous vein is formed by the dorsal venous arch of the foot, and the dorsal vein of the little toe. It moves up the posterior side of the leg, passing posteriorly to the lateral malleolus. |
| B | The great saphenous vein is formed by the dorsal venous arch of the foot, and the dorsal vein of the great toe. It ascends up the medial side of the leg, passing anteriorly to the medial malleolus at the ankle, and posteriorly to the medial condyle at the knee. |
| C | Deep veins are located underneath the deep fascia of the lower limb, accompanying the major arteries. |
| D | **Obviously near popliteal fossa** |
| E | **Merging of Sephanous and femoral vein in the Inguinal region** |
| **KEY** | **A** |
| Additional Information | **Apologies the diagram should be here but I think one mistake is allowed** <br> *Long standing Varicose veins: stasis of blood causes pigmentation* |
| **Reference** | |

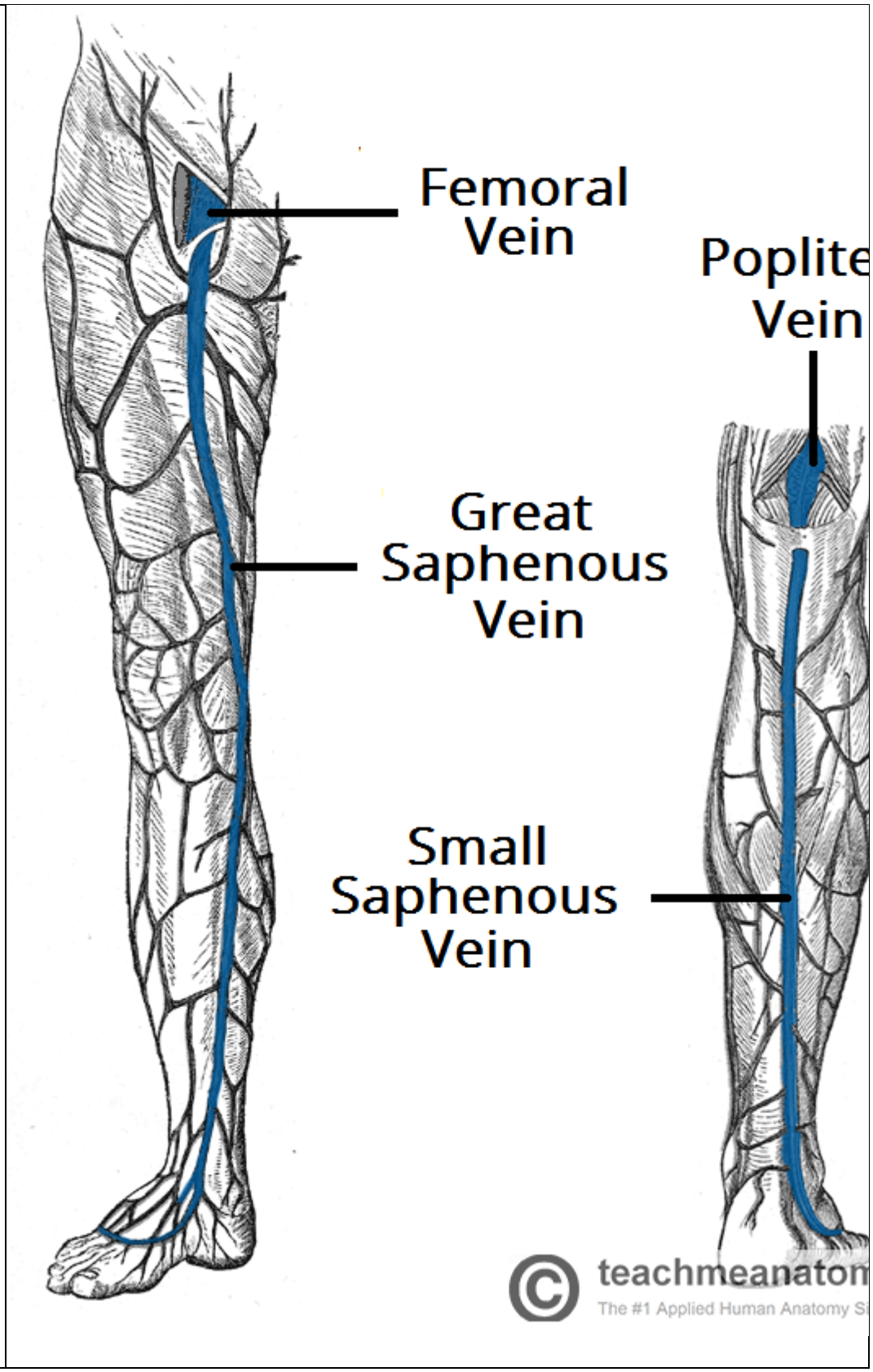


| | |
|---|---|
| **Q:447** | A pt presents with weight loss of 5kgs despite good appetite. He also |

| | |
|---|---|
| | complains of palpitations, sweating and diarrhea. He has a lump in front of his neck which moves on swallowing. What is<br>the most appropriate dx?<br>a. Lymphoma<br>b. TB adenitis<br>c. Thyroid Ca<br>d. Goiter<br>e. Thyroid cyst |
| | |
| **Clincher(s)** | **Weight loss with good appetite, diarrhoea ,sweating, palpitation, lump in the neck which moves on swallowing.** |
| A | Not the case here |
| B | Again doesn't fit in this particular scenario. Just FYI<br>Tuberculous lymphadenitis (or tuberculous adenitis) is a chronic specific granulomatous inflammation of the lymph node with caseation necrosis, caused by infection with Mycobacterium tuberculosis or Mycobacterium |
| C | Solitary thyroid nodules can vary from soft to hard. Hard and fixed nodules are more suggestive of malignancy than soft mobile nodules. Thyroid carcinoma is usually non-tender to palpation. |
| D | **Typical symptoms that are fitting perfectly for this scenario (hyperthyroidism)** |
| E | **it is important to note that the cyst moves upwards when the patient protrudes the tongue.** |
| **KEY** | **D** |
| Additional Information | **<u>All the info is on ohcm pg 210</u>** |
| **Reference** | Patient info |

| | |
|---|---|
| **Q:457** | 457. A 72yo woman who had a repair of strangulated femoral hernia 2 days ago becomes noisy, aggressive and confused. She is febrile, CBC normal apart from raised MCV (alcoholic- B12 not absorbtion – malnutrition- meaglobastic anemia). What is the most likely dx?<br>a. Electrolyte imbalance<br>b. Delirium tremens<br>c. Wernickė̇s encephalopathy<br>d. Infection toxicity<br>e. Hypoglycemia |
| | |
| **Clincher(s)** | **Elderly, hospitalised, MCV raised, noisy, confused and aggressive** |
| A | Electrolyte imbalance does fit with confusion but raised MCV means the pathology is not related to electrolytes. |
| B | Alcohol withdrawal delirium or 'delirium tremens' (can appear 48-72 hours after alcohol has stopped. (If tremens: alcohol involvement) |

| | |
|---|---|
| C | Wernicke's encephalopathy presents as a classical triad of confusion, ataxia ( wide based gait) and opthalmoplegia ( nystagmus, double vision) |
| D | **No signs of infection apart from being febrile. CBC count normal plus I think toxicity does presents a bit later and two day after surgery is a bit too early** |
| E | **Hypoglycaemia can cause confusion but mainly drowsy and anxious instead of being noisy.** |
| **KEY** | **B** |
| Additional Information | **Delirium tremens usually begins 24-72 hours after alcohol consumption has been reduced or stopped.**<br><br>**The symptoms/signs differ from usual withdrawal symptoms in that there are signs of altered mental status. These can include:**<br><br>**Hallucinations (auditory, visual, or olfactory).**<br><br>**Confusion.**<br><br>**Delusions.**<br><br>**Severe agitation.**<br><br>**Sedation with benzodiazepines is suggested. Diazepam has a rapid onset of action**<br><br>NICE: 1.3.5.3 Prescribe and administer medication for assisted withdrawal within a standard clinical protocol. The preferred medication for assisted withdrawal is a benzodiazepine (chlordiazepoxide or diazepam).<br><br>Additional info by Sami ☺ ☐So the liver produces enzymes that are essential for folic acid and alcohol could affect these enzymes leading to megaloblastic anemia. Increased red blood cell size (Mean Cell Volume, or MCV): A good indicator of someone having recently ingested alcohol is the "mean corpuscular volume" of the red blood cells. If the person has recently had alcohol to drink, the cells become large, so the MCV is high, usually 100 or more. This happens as a result of several factors -- direct effect on the red blood cell membrane, vitamin deficiencies i.e. folate or direct effect on the bone marrow.The increased red blood cell size is due to bone marrow toxicity from alcohol use.<br><br>*Alcoholic patients will have raised MCV* |

| | |
|---|---|
| | **Withdrawal** starts 10–72h after last drink. *Signs:* Pulse↑; BP↓; tremor; confusion; fits; hallucinations (*delirium tremens*)—may be visual or tactile, eg animals crawling all over skin. Consider it in any new (≤3d) ward patient with acute confusion. |
| **Reference** | Patient info , OHCM 282 |

| | |
|---|---|
| **Q:474** | L1 level, what is the most appropriate landmark?<br>a. Mcburney's point<br>b. Stellate ganglion<br>c. Deep inguinal ring<br>d. Termination of the spinal cord<br>e. Transpyloric plane |
| | |
| **Clincher(s)** | **L1 and most prominent landmark** |
| A | McBurney's point is the name given to the point over the right side of the abdomen that is one-third of the distance from the anterior superior iliac spine to the umbilicus (navel). (where the pain of Acute Appendicitis happens) |
| B | The stellate ganglion is a collection of nerves (sympathetic) found at the level of the sixth and seventh cervical vertebrae (the last vertebra of the neck). The nerves are located in front of the vertebrae. They are part of the sympathetic nervous system and supply the face and arm |
| C | The surface marking of the deep inguinal ring (DIR) is commonly described as being located at either the middle of the inguinal ligament (MIL) or at the mid-inguinal point (MIP); |
| D | **The point at which the spinal cord ends is called the conus medullaris, and is the terminal end of the spinal cord. It occurs near lumbar nerves L1 and L2. After the spinal cord terminates, the spinal nerves continue as a bundle of nerves called the cauda equina.** |
| E | **Described below in a diagram** |
| **KEY** | **E** |

| | |
|---|---|
| Additional Information | **TRANSPYLORIC PLANE**<br>(Horizontal line half way between suprasternal notch & pubic symphysis)<br> 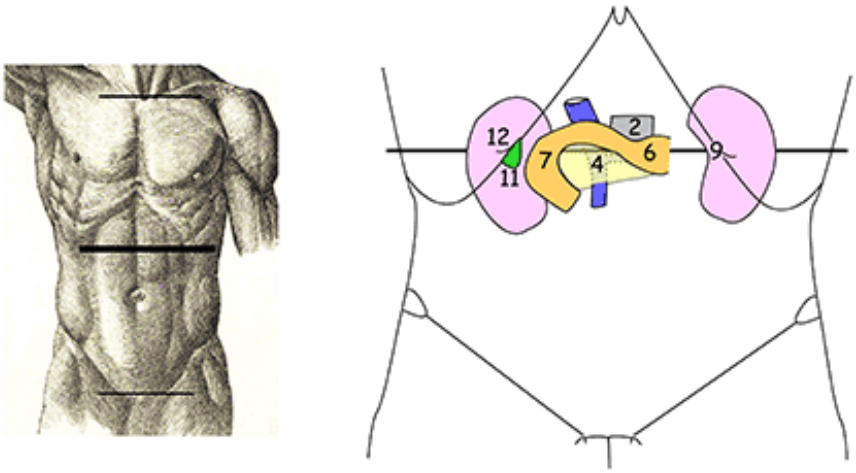 <br><br>Structures approximately on this line:<br>1 End of spinal cord<br>2 L1 vertebral body<br>3 Origin of superior mesenteric art<br>4 Origin of portal vein<br>5 Neck of pancreas<br>6 Pylorus of the stomach<br>7 Second part of duodenum<br>8 Sphincter of Oddi<br>9 Hilum of each kidney<br>10 Duodenojejunal flexure<br>11 Fundus of gall bladder<br>12 Tips of ninth costal cartilages |
| **Reference** | Various websites |

| | |
|---|---|
| **Q: 814** | A 68yo man has had increasing dysphagia for solid food for 3m and has lost 5kgs in weight. What single inv is most likely to lead to a def dx?<br>a. Barium swallow<br>b. CXR<br>c. CT chest<br>d. Endoscopy and biopsy<br>e. Video-fluoroscopy |
| | |

| **Clincher(s)** | **Age above 45, increasing dysphagia(progressive) to solids, weight loss.** *(point toward malignancy)* |
|---|---|
| A | Barium swallow is done for achalasia, Oesophageal spasm and benign or malignant stricture. |
| B | CXR has no diagnostic benefits in this particular case. |
| C | CT chest is done in the staging of oesophageal carcinoma. |
| D | **Endoscopy and biopsy is the best investigation for diagnosis of oesophageal carcinoma.** |
| E | Video-flouroscopy is just like barium swallow and can be advised in the investigation of dysmotility disorders. e.g achalasia and esophageal spasm. |
| **KEY** | **D (always for eso can- do biopsy)** |

Additional Information(according to the MCQS point of view)

OHCS PG 274 & OHCM PG 240

# Dysphagia

Dysphagia is difficulty in swallowing and always needs investigating urgently to exclude malignancy (unless of short duration, and associated with a sore throat).

**Causes** Oral, pharyngeal, or oesophageal? Mechanical or motility related? (See BOX.)

**5 key questions to ask**

1. Was there difficulty swallowing solids **and** liquids from the start? (See BOX.)
   **Yes:** motility disorder (esp if non-progressive, eg achalasia, CNS, or pharyngeal causes).
   **No:** Solids **then** liquids: suspect a stricture (benign or malignant).
2. Is it difficult to make the swallowing movement?
   **Yes:** Suspect bulbar palsy, especially if patient coughs on swallowing.
3. Is swallowing painful (odynophagia)?
   **Yes:** Suspect cancer, oesophageal ulcer (benign or malignant), *Candida* (eg immunocompromised or poor steroid inhaler technique) or spasm.
4. Is the dysphagia intermittent or is it constant and getting worse?
   **Intermittent:** Suspect oesophageal spasm.
   **Constant and worsening:** Suspect malignant stricture.
5. Does the neck bulge or gurgle on drinking?
   **Yes:** Suspect a pharyngeal pouch (see *OHCS* p573).

**Signs** Is the patient cachectic or anaemic? Examine the mouth; feel for supraclavicular nodes (left supraclavicular node = Virchow's node—suggests intra-abdominal malignancy); look for signs of systemic disease, eg systemic sclerosis (p554), CNS disease.

**Tests** FBC (anaemia); U&E (dehydration); CXR (mediastinal fluid level, no gastric bubble, aspiration). Upper GI endoscopy ± biopsy—in high dysphagia, precede by barium swallow (fig 1) for pharyngeal pouch (± ENT opinion). 2nd-line: video fluoroscopy to identify dysmotility, eg achalasia. Oesophageal manometry if barium swallow is normal.

**Specific conditions** *Oesophagitis* p244. *Diffuse oesophageal spasm* causes intermittent dysphagia ± chest pain. Barium swallow: abnormal contractions, eg corkscrew oesophagus.[1] *Achalasia:* The lower oesophageal sphincter fails to relax (due to degeneration of the myenteric plexus), causing dysphagia (for fluids and solids), regurgitation, substernal cramps, and ↓weight. CXR: fluid level in dilated oesophagus (eg above heart); barium swallow: dilated tapering oesophagus. Treatment: endoscopic balloon dilatation, or Heller's cardiomyotomy—then proton pump inhibitors (PPIs, p244). Botulinum toxin injection if a non-invasive procedure is needed (repeat every few months).[37] Calcium channel blockers and nitrates also relax the sphincter. Longstanding achalasia may cause oesophageal cancer. *Benign oesophageal stricture:* Caused by gastro-oesophageal reflux (GORD, p244), corrosives, surgery, or radiotherapy. Treatment: endoscopic balloon dilatation. *Oesophageal cancer:* (p620). Associations: ♂, GORD,[38] tobacco, alcohol, Barrett's oesophagus (p709), achalasia, tylosis (palmar hyperkeratosis), Paterson-Brown-Kelly (Plummer-Vinson) syndrome (post-cricoid dysphagia, upper oesophageal web + iron-deficiency). *CNS causes:* Ask for help from a speech rehab specialist.

# Oesophageal tumours

## Key facts and pathological features

There are several types of oesophageal tumours.

***Adenocarcinoma***

- Rapidly increasing incidence in western world; ♂:♀, 5:1.
- Commonest in Western Europe.
- Associated with dietary nitrosamines, GORD, and Barrett's metaplasia.
- Most commonly occurs in the lower third of the oesophagus.

***Squamous carcinoma***

- Incidence slightly reducing in western world. Commonest in Japan, northern China, and South Africa; ♂:♀, 3:1.
- Associated with smoking, alcohol intake, diet poor in fresh fruit and vegetables, chronic achalasia, chronic caustic strictures.
- May occur anywhere in the oesophagus.

***Rhabdomyo(sarco)ma*** Malignant tumour of skeletal muscle wall of the oesophagus; very rare.

***Lipoma and gastrointestinal stromal tumours*** (GIST, see 📖 p. 292) Rare.

## Clinical features

- *Dysphagia.* Any new symptoms of dysphagia, especially over the age of 45, should be assumed to be due to tumour until proven otherwise.
- *Haematemesis.* Rarely the presenting symptom.
- *Incidental/screening.* Occasionally identified as a result of follow-up/screening for *Barrett's metaplasia*, achalasia, or reflux disease. Presence of high grade dysplasia in Barrett's is associated with the presence of an occult adenocarcinoma in 30%.
- *Features of disseminated disease.* Cervical lymphadenopathy, hepatomegaly due to metastases, epigastric mass due to para-aortic lymphadenopathy.
- *Symptoms of local invasion.* Dysphonia in recurrent laryngeal nerve palsy, cough and haemoptysis in tracheal invasion, neck swelling in superior vena cava (SVC) obstruction, Horner's syndrome in sympathetic chain invasion.

| | |
|---|---|
| **Q: 816** | Anatomical structure to be pierced during surgery midline port during gallstone removal.<br>a. External iliac muscle<br>b. Cricoid cartilage<br>c. Linea alba<br>d. Rectus sheath muscle<br>e. Duramater<br>f. 1st tracheal cartilage<br>g. Conjoined tendon<br>h. Intercostal muscles |
| | |
| **Clincher(s)** | **straight forward questions** |
| A | This muscle is pierced in lateral ports insertion. *(There is no 'external' iliac muscle)* |
| B | cricoid cartilage is in neck. just above trachea. |
| C | **Linea alba is a midline fascia between two rectus muscles. and it is incised for midline access in laparoscopy.** |
| D | Rectus sheath is a fascia covering muscles. |
| E | Duramater is covering of brain. |
| F | Ist tracheal ring. *For tracheostomy- we incise 2nd and 3rd tracheal ring.* |
| G | conjoined tendon is formed by common aponeurosis of internal oblique and transverses abdominis muscles when it inserts on pubic crest. |
| H key | Intercostal muscles are located in the chest. (Skype: for chest tube insertion) |

| | |
|---|---|
| Additional Information | **Steps of surgery**<br>• *Skin incision.* Scalpel or cutting diathermy with needle point electrode.<br>• *Fat incision.* Blend diathermy to reduce risk of bleeding.<br>***Midline access*** (see 📖 p. 82)<br>• *Midline fascia (linea alba) incision.* At or above the umbilicus (pre-peritoneal fat reduces the risk of underlying bowel injury). The midline can be identified by the presence of oblique crossing/interleaved fascial fibres. Expose fascia, elevated with clips to generate negative intra-abdominal pressure and sharply incised.<br>• *Access extension.* With blend diathermy in the midline.<br>***Paramedian access*** |
| **Reference** | OHCS PG 730 & 732 |

| | |
|---|---|
| **Q:820** | Inserting a drain in the mid-axillary line. What is the single most appropriate anatomical structure?<br>a. External iliac muscle<br>b. Linea alba<br>c. Rectus sheath muscle<br>d. Conjoined tendon<br>e. Intercostal muscles |
| | |
| **Clincher(s)** | Chest drain. |
| A | external iliac muscle- there is iliacs muscles but there is no external iliac muscle |
| B | Linea alba is significant abdominal incisions. |
| C | Rectus sheath muscle significant in abdominal surgery. |
| D | Conjoined tendon in inguinal hernia surgery. |
| E | **Intercostal muscles are the muscle between two ribs that are pierced while inserting chest drain.** |
| **KEY** | **E** |

Additional Information

# Chest drain insertion

## Key facts

There are three main options for most patients with pleural effusions or pneumothoraces that need intervention:

- *Needle thoracentesis.* Used for first-time treatment of simple effusions or pneumothoraces with low likelihood of recurrence.
- *Pigtail thoracostomy.* A 16G tube inserted using modified Seldinger technique; good for simple pneumothorax or effusion.
- *Chest tube.* Large bore tube inserted, either blunt (recommended) or using trocar to treat tension pneumothorax, recurrent pneumothorax, haemothorax, or empyema. Indications are listed below.

## Indications (British Thoracic Society guidelines)

- Pneumothorax.
  - In any ventilated patient.
  - Tension pneumothorax after initial needle relief.
  - Persistent or recurrent pneumothorax after simple aspiration.
  - Large secondary spontaneous pneumothorax in patients over 50y.
- Malignant pleural effusion.
- Empyema and complicated parapneumonic pleural effusion.
- Traumatic haemopneumothorax.
- Post-operative, e.g. thoracotomy, oesophagectomy, cardiac surgery.

## Equipment

*Chest tube on lower side of intercostal space,*

*To prevent injury to Neurovascular bundles*

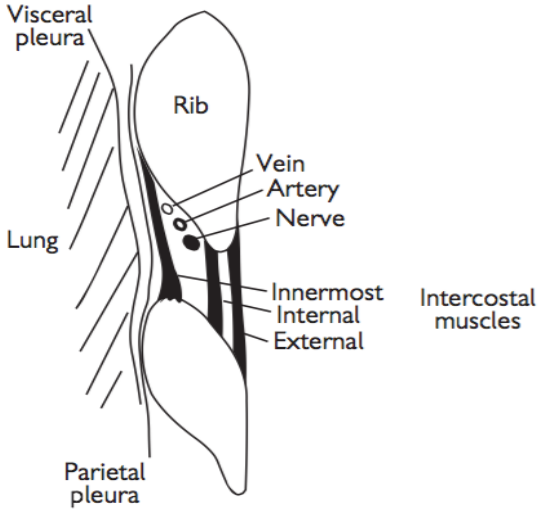


**4.4** Anatomy of the intercostal space.

| **Reference** | OHCS PG 200 & 201 |
|---|---|

| **Q:828** | A child is not breathing and intubation failed. At what anatomical site should the incision be made?<br>a. External iliac muscle<br>b. Cricoid cartilage<br>c. Linea alba<br>d. Rectus sheath muscle<br>e. Duramater<br>f. 1st tracheal cartilage<br>g. Conjoined tendon<br>h. Intercostal muscles |
|---|---|
| | |
| **Clincher(s)** | **Intubation failed.** |
| A | not relevant |
| B | Cricoidotomy- Incision in cricoid membrane (Emergency procedure). |
| C | linea alba for abdominal surgery. |
| D | Rectus abdominis muscle is significant in the abdominal surgery. |
| E | Dura mater is a brain covering. |
| F | Ist tracheal cartilage is spared. However, 2nd and 3rd tracheal ring are incised in the tracheostomy. |
| G | Conjoined tenden for inguinal surgery. |
| H | Intercostal muscles for chest drain and thoraci incisions. |
| **KEY** | **B Cricoid cartiliage.** |

| | |
|---|---|
| Additional Information | |

# Cricothyroidotomy

Go to p

## Indications

***Emergency need for a surgical airway***

- Major maxillofacial injury.
- Oral burns.
- Fractured larynx.
- Need for tracheal toilet in the extubated patient.

### Needle cricothyroidotomy

- Patient peri-arrest.
- Use the landmarks described below.
- Omit local anaesthetic infiltration, cut-down, and dissection.
- Pass a 12G (brown or larger) needle directly though the cricoid membrane.
- Oxygenate using jet insufflation until a formal airway can be established.

## Equipment

- Minitracheostomy, size 6.0 ET tube or 12G cannula in emergencies.
- Artery forceps.
- 10mL 1% lidocaine.
- 10mL syringe.
- Blue needle and a green needle.
- 20mL saline.
- 2 or 3/0 silk on a large handheld needle.
- 11-blade scalpel.
- Skin prep.
- Sterile drape.
- Sterile gloves and gown.
- Gauze swabs.

## Preparation

- Explain procedure to the patient where appropriate.
- The trauma patient's C-spine should be immobilized in the neutral position.

## Landmarks

The cricoid membrane is a small diamond-shaped membrane, palpable just below the prominence of the thyroid cartilage.

## Technique (see Fig. 4.6)

- Prep and drape, put on sterile gloves.
- If the patient is conscious and maintaining their own airway, infiltrate local anaesthetic using aseptic technique.
- Stabilize the thyroid cartilage with the left hand.
- With your right hand, make a 2cm transverse incision (smaller for minitracheostomy) through the skin overlying the cricothyroid membrane and then straight through the cricothyroid membrane.
- Now turn the scalpel blade 90° within the airway so that it acts as a temporary retractor.

| | |
|---|---|
| | |

**Reference**
**OHCS PG 206 & 207**

- Place an artery forceps through the incision and open it, remove the scalpel, and insert a size 6.0 ET tube.
- Suction the tube, secure, and connect to a source of oxygen.
- Some minitracheostomy kits use the Seldinger technique; aspirating air freely is a sign that the needle is in the trachea and that a guidewire can be gently passed down the lumen.

## Complications

- Bleeding.
- Loss of airway.
- Recurrent laryngeal nerve injury.
- Vocal cord injury.

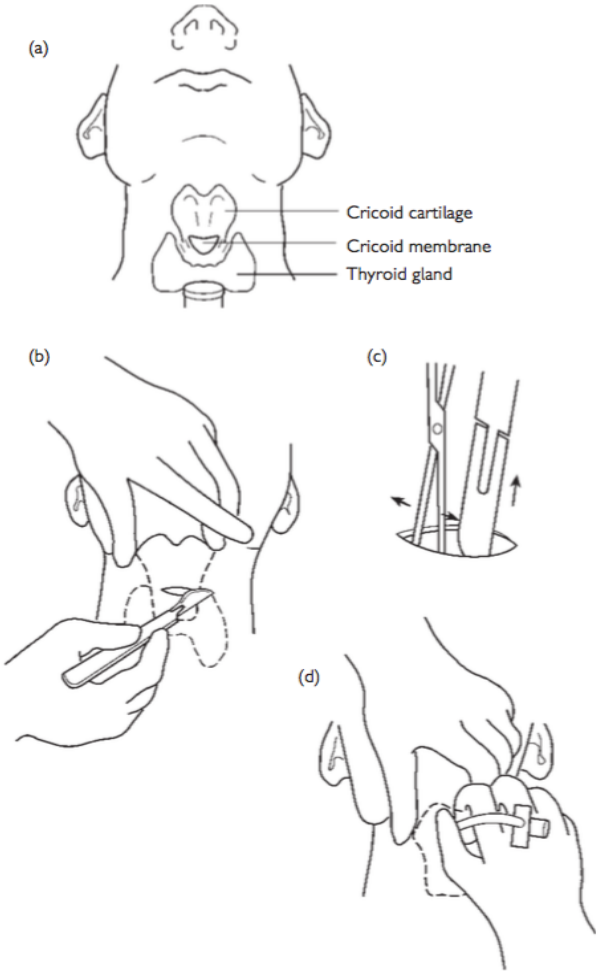


**Fig. 4.6** Technique of cricothyroidotomy. (a) Structures involved. (b) Incision. (c) Keeping cricothyroidotomy patent. (d) Inserting mini-thyroidostomy.

*If there is failure of intubation: emergency cricoid surgery will be done*

| | |
|---|---|
| **Q:1404** | A 23yo woman presents with a 1cm small smooth, firm, mobile mass in her left breast. She is very anxious. What is the most appropriate inv?<br>a. Mammography<br>b. US breast<br>c. FNAC<br>d. Mammography and US |
| | |
| **Clincher(s)** | **young age, 1cm small smooth muscle.** |
| A | Mammography in female age above 35 |
| B | Ultrasound in female age below 35 |
| C | FNAC if suspicion on radiological imaging |
| D | Mammography and US is not done together |
| | |
| **KEY** | **B Ultrasound breast.** *(Firboadenoma/fibrocystic disease) For any lump in the breast (US <35 and >35; if benign, cystic or if malignant> underlying: Mamography, to confirm: FNAC, then , biopsy (Tripple assessment for Ca suspicion: clinical, radiological and tissue diagnosis)* |

| | |
|---|---|
| Additional Information | **Clinical features**<br>***Breast lump***<br>• Commonest presenting symptom.<br>• Usually painless (unless inflammatory carcinoma).<br>• Hard and gritty feeling.<br>• May be immobile (held within breast tissue), tethered (attached to surrounding breast tissue or skin), or fixed (attached to chest wall).<br>• Ill-defined; irregular with poorly defined edges.<br>**Diagnosis and investigation**<br>***Diagnostic tests***<br>• All breast lumps or suspected carcinomas are investigated with triple assessment.<br>• Clinical examination (as above).<br>• Radiological assessment:<br>  • *Mammography usual*, particularly over age 35y.<br>  • *Ultrasound scan* used to assess the presence of involved lymph nodes; sometimes used under age 35 because increased tissue density reduces sensitivity and specificity of mammography.<br>  • *MRI* used in lobular carcinoma to assess the extent of the disease, multifocality, and the opposite breast.<br>• *Younger women with dense breast tissue*. For screening purpose in patients with strong family history.<br>***Tissue diagnosis***<br>• Core biopsy or fine needle aspiration cytology (FNAC) of the breast lesion ± axillary nodes.<br>• Core biopsy also finds oestrogen receptor status, differentiates between invasive carcinomas and *in situ* carcinoma (ductal carcinoma *in situ*, DCIS).<br>***Staging investigations*** |
| **Reference** | OHCS PG 240 & 241 |

| | |
|---|---|
| **Q:753** | A 20yo male smoker is noted to have intense rubor of the feet and absent foot pulse. Exam: amputated right 2nd toe . What is the most probable dx? a. Intermittent claudication<br>b. Cardiovascular syphilis<br>c. Buerger's disease<br>d. Embolism<br>e. Acute limb ischemia |
| | |
| **Clincher(s)** | **Smoker,rub or,absent foot pulse** |
| A | Common in people older than 50 years,muscle pain in lower limbs on exercise,most common cause is peripheral arterial disease,diagnosed by magnetic resonance angiography,duplex ultrasonography Treatment by ACE -,beta blockers,anti platelets,stunting,angioplasty,atherectomy,surgery bypass last resort |
| B | Cases of cardiovascular syphilis may be divided into following groups. Occult type or asymptomatic.<br>Simple aortitis type. Aortic<br>Regurgitant type<br>Aneurysmal type.<br>Coronary Occlusive type. Myocarditis<br>type.<br>Peripheral vascular type.<br>Neurovascular type.<br>Was sermons reaction diagnosed,<br>Treated with penicillin,doxycycline,antibiotics |
| C | Or thromboangitis obliterans |
| D | **An embolism is a condition where the blood flow in an artery is blocked by a foreign body, such as a blood clot or an air bubble.**<br>**Two of the most serious conditions caused by an embolism are: stroke – where the supply of blood to the brain is interrupted or cut off pulmonary embolisms – when a foreign body blocks the artery transporting blood to the lungs** |
| E | **Peripheral arterial disease (PAD) occurs when there is significant narrowing of arteries distal to the arch of the aorta, most often due to atherosclerosis. Symptoms vary from calf pain on exercise (intermittent claudication) to rest pain (critical limb ischaemia), skin ulceration and gangrene. Patients diagnosed as having PAD, including those who are asymptomatic, have an increased risk of mortality, myocardial infarction and stroke. Risk factors**<br>**Smoking.**<br>**Diabetes mellitus.**<br>**Hypertension.**<br>**Hyperlipidaemia: high total cholesterol and low high-density lipoprotein (HDL) cholesterol are independent risk factors.** |

| | |
|---|---|
| | **Physical inactivity.**<br>**Obesity.**<br>**Epidemiology**<br>**PAD affects 4-12% of people aged 55-70 years and 15-20% of people aged over 70 years. History**<br>**The history should include a history of cardiovascular disease and an assessment of risk factors, including hypertension, dyslipidaemia, diabetes mellitus and smoking status. Any family history of cardiovascular disease is also important. Many patients with PAD are asymptomatic but still at high risk of cardiovascular events.** |
| **KEY** | **C** |
| Additional Information | **What is Buerger's Disease?**<br><br>**Buerger's (also known as Thromboangiitis obliterans) is a disease of the small and medium arteries and veins that restricts blood flow to the hands and feet. Clots (thrombus) develop inside the blood vessels. This in turn leads to skin ulcers and gangrene in the fingers and toes and numbness and tingling if the nerves are affected. It is not uncommon for toes, fingers and limbs to need to be amputated if the gangrene progresses. It is not clear whether this is a true vasculitis.**<br><br>**Who are affected?**<br><br>**The disease is seen almost exclusively in smokers, mainly in young men aged 20-40 years. Recently, however, a higher percentage of women and patients over 50 have been diagnosed.**<br><br>**What are the symptoms?**<br><br>**The initial symptoms include claudication (pain induced by insufficient blood flow during exercise) in the feet and or the hands. The pain usually begins in the extremities but may radiate to other parts of the body. Patients may experience numbness and tingling in the limbs and also Raynaud's Phenomenon. Raynaud's is a condition where the extremities of the hands and feet turn white when exposed to cold. A common sign in Buerger's is skin ulceration and gangrene of the fingers and toes**<br><br>**What is the aetiology (cause)?**<br><br>**Use of tobacco, particularly cigarette smoking, is the overwhelming factor predisposing to a diagnosis of Buerger's Disease. The majority of patients are heavy smokers, although some cases have been reported in moderate smokers and even in patients using chewing tobacco or other forms of** |

| | |
|---|---|
| | **tobacco that are not smoked. It is thought that this disease is triggered by some constituent of tobacco.**<br><br>**Diagnosis**<br><br>**Angiograms of the limbs can be helpful in making a diagnosis of the disease. Biopsies are not usually recommended as a diagnostic tool for Buerger's Disease because of the possibility that the biopsy area may not heal well. Typically blood tests are normal and do not show any evidence of inflammation.**<br><br>**Treatment**<br><br>**It is essential that people affected with Buerger's Disease stop smoking completely and immediately. Continued smoking or use of other forms of tobacco, even small amounts, increases the risk of losing fingers, toes or limbs due to necessary amputation.**<br><br>**Although there is evidence of inflammation inside the vessels and within the blood clots this differs from other types of vasculitis were the inflammation is in the blood vessel wall. Anti-inflammatory andimmunosuppressant treatments have not been shown to be effective in Buerger's Disease. Other treatments such as iloprost or prostacyclin that help to open up the blood vessels may be helpful.** |
| **Reference** | Nice,NHS.co.uk |
| Dr Khalid/Rabia | Buerger's disease. [ The traditional diagnosis of Buerger's disease is based on 5 criteria (smoking history, onset before the age of 50 years, infrapopliteal arterial occlusive disease,<br>either upper limb involvement or phlebitis migrans, and absence of atherosclerotic risk factors other<br>than smoking). As there is no specific diagnostic test and an absence of positive serologic markers,<br>confident clinical diagnosis should be made only when all these 5 criteria have been fulfilled]. |

| | |
|---|---|
| **Q:774** | A 33yo female presents with sudden severe colicky abdominal pain in her RIF. A mobile mass is felt on examination. What is the most likely dx? a. PID<br>b. Appendicitis<br>c. Ovarian torsion<br>d. Constipation |
| | |
| **Clincher(s)** | |
| A | Back ache,discharge pv,some times fever |
| B | No mass felt ,no mass felt |
| C | the incidence among women of reproductive age (15−45 years) |
| D | **It's RIF pain so ruled out** |
| E | |
| **KEY** | **Ovarian torsion** |
| Additional Information | **It's a 3% of gynaecological emergenciesPatients with ovarian torsion often present with sudden onset of sharp and usually unilateral lower abdominal pain, in 70% of cases accompanied by nausea and vomiting.**<br>**Pathophysiology:**<br><br>**The development of an ovarian mass is related to the development of torsion. In the reproductive years, regular growth of large corpus luteal cysts are a risk factor for rotation. The mass effect of ovarian tumors is also a common cause of torsion. Torsion of the ovary usually occurs with torsion of the fallopian tube as well on their shared vascular pedicle around the broad ligament, although in rare cases the ovary rotates around the mesovarium or the fallopian tube rotates around the mesosalpinx. In 80%, torsion happens unilaterally, with slight predominance on the right.**<br><br>**Doppler USG showsLittle or no intra-ovarian venous flow. This is commonly seen in ovarian torsion.**<br><br>**Absent arterial flow. This is a less common finding in ovarian torsion**<br><br>**AbseEnlarged hypoechogenic or hyperechogenic ovary**<br><br>**Peripherally displaced ovarian follicles**<br><br>**Free pelvic fluid. This may be seen in more than 80% of cases**<br><br>**Whirlpool sign of twisted vascular pedicle**<br><br>**Underlying ovarian lesion can often be found** |

| | |
|---|---|
| | **Uterus may be slightly deviated towards the torted ovary. Treatment is laparoscopy** |
| **Reference** | Nice guidelines |
| Dr Khalid/Rabia | |

| | |
|---|---|
| **Q:785** | A 44yo woman with breast cancer had an extensive removal and LN clearance. She needs an adjunctive tx. Her mother had cancer when she was 65. Which of the following factors will be against the tx?<br>a. Fam hx<br>b. Tumor grading<br>c. LN involvement<br>d. Her age<br><br>New adjuvant- given before surgery<br>Adjuvant- chemo radio after surgery |
| | |
| **Clincher(s)** | **Age of the patient ,breast cancer,adjunctive treatment** |
| A | Given |
| B | Given |
| C | Given |
| D | **Not the criteria** |
| E | |
| **KEY** | **D** |

| | |
|---|---|
| Additional Information | **Adjuvant treatment is the administration of additional therapy after primary surgery to kill or inhibit micrometastases. Primary surgery for breast cancer is accomplished by lumpectomy followed by whole-breast irradiation or by mastectomy. Adjuvant treatment may include local irradiation after mastectomy, systemic therapy with cytotoxic chemotherapy, or endocrine therapy**<br>**Tamoxifen is effective in both premenopausal and postmenopausal women with hormone-sensitive**<br>**Anthracycline based chemotherapy**<br>**And adjuvant radiotherapy**<br>**Chemotherapy after surgery is given in following conditions:**<br><br>**The lymph nodes under your arm contained breast cancer cells** |
| | **You had a large primary cancer in the breast**<br><br>**Your breast cancer cells were high grade (grade 3)**<br><br>**Your cancer cells did not test positive for hormone receptors and so are not likely to respond well to hormone therapy** |
| **Reference** | Nhs |
| Dr Khalid/Rabia | |

| | |
|---|---|
| **Q:789** | man presents with abdominal pain, vomiting, pulse=120bpm, BP=90/60mmHg and a rigid abdomen. His chest is clear. What is the immediate management?<br>a. Call radiology<br>b. Admit to medical ward<br>c. Urgent admission to ITU |
| | 60yo man presents with weight loss and Hgb=6. Hx reveals that he has abdominal pain and diarrhea for the past 6m. What is the most appropriate inv? a. Barium enema<br>b. Colonoscopy<br>c. Sigmoidoscopy |
| **Clincher(s)** | **All intrabdominal pathology can lead to peritonitis- not a long hx- days and hours-** |
| A | |
| B | |
| C | |
| D | |
| E | |
| **KEY** | **C** |

| | |
|---|---|
| Additional Information | presenting features are consistent with Colonic carcinoma.<br>Risk factors<br>· Family history of colorectal neoplasia: carcinoma; adenoma under the age of 60 years.[3]<br>· Past history of colorectal neoplasm: carcinoma, adenoma.<br>· Inflammatory bowel disease: ulcerative colitis, Crohn's colitis.<br>· Polyposis syndromes: familial adenomatous polyposis (Gardner's syndrome), Turcot's syndrome, attenuated adenomatous polyposis coli, flat adenoma syndrome, hamartomatous polyposis syndromes (Peutz-Jeghers syndrome, juvenile polyposis syndrome, Cowden's syndrome).<br>· Hereditary non-polyposis colorectal cancer (HNPCC).<br>· Hormonal factors: nulliparity, late age at first pregnancy, early menopause.<br>· Diet: rich in meat and fat; poor in fibre, folate and calcium.<br>· Sedentary lifestyle, obesity, smoking, high alcohol intake. ·<br>Diabetes mellitus. |
| | · Previous irradiation, occupational hazards - eg, asbestos exposure.<br>· History of small bowel cancer, endometrial cancer, breast cancer or ovarian cancer.<br>Presentation<br>· The presentation depends on the site of the cancer:<br>· Right colon cancers: weight loss, anaemia, occult bleeding, mass in right iliac fossa, disease more likely to be advanced at presentation.<br>· Left colon cancers: often colicky pain, rectal bleeding, bowel obstruction, tenesmus, mass in left iliac fossa, early change in bowel habit, less advanced disease at presentation.<br>· The most common presenting symptoms and signs of cancer or large polyps are rectal bleeding, persisting change in bowel habit and anaemia.<br>· All patients with symptoms suspicious of colorectal cancer must have a thorough abdominal examination and rectal examination.<br>Inv:<br>Colonoscopy and biopsy<br>Ct for staging<br>Rx<br>Surgery<br>Chemo radio for advanced cases |
| **Reference** | |
| Dr Khalid/Rabia | Rabia |

| | |
|---|---|
| **Q:** | 1543. A lady with post ileocolectomy closure of stoma has a small 4 cm swelling around the stoma. What is the most appropriate management of the swelling?<br>a. Local exploration of swelling<br>b. Exploratory laparotomy<br>c. Open laparotomy and re-closure<br>d. Abdominal binder<br>e. Truss (tech for abs incisional hernia)<br>f. Laparotomy with mesh repair |
| | |
| **Clincher(s)** | **Post op 4cm swelling** |
| A | It's not causing harm to the patient |
| B | Pt is stable so no operation |
| C | Since patient is stable and as it looks like post op hernia we need to use conservative treatment first |
| D | **Yes to be used** |
| E | **Truss is a supportive device usually a pad with a belt worn to prevent enlargement of hernia or the return of a reduced hernia** |
| **KEY** | **D – only a supportive treatment**<br><br>**If was given – fever and inflammation- it would be option A**<br>**Immediately after surgery: 1) local abscess (mostly) or 2) weakness in abd wall (abd binder)**<br><br>**If after many months- after recovery- inscional hernia** |

| | |
|---|---|
| Additional Information | ( Most hernias can be managed without surgery. Support belts and appliances are the most successful aids. These are available on prescription in the UK) Parastomal hernia<br>A parastomal hernia involves an ostomy in the area where the stoma exits the abdominal cavity. The intestine or bowel extends beyond the abdominal cavity or abdominal muscles; the area around the stoma appears as a swelling or protuberance. Parastomal hernias are incisional hernias in the area of the abdominal musculature that was incised to bring the intestine through the abdominal wall to form the stoma. They may completely surround the stoma (called circumferential hernias) or may invade only part of the stoma.<br>Parastomal hernias can occur any time after the surgical procedure but usually happen within the first 2 years. Recurrences are common if the hernia needs to be repaired surgically. Risk factors may be patient related or technical. Patientrelated risk factors include obesity, poor nutritional status at the time of surgery, presurgical steroid therapy, wound sepsis, and chronic cough. Risk factors related to technical issues include size of the surgical opening and whether surgery was done on an emergency or elective basis.<br>Parastomal hernias occur in four types. Initially, a parastomal hernia begins as an unsightly distention in the area surrounding the stoma; the hernia enlarges, causing pain, discomfort, and pouching problems resulting in peristomal skin complications that require frequent assessment. Conservative therapy is the usual initial treatment. Adjustments to the pouching system typically are required so changes in the shape of the pouching surface can be accommodated. Also, a hernia support binder or pouch support belt may be helpful. Avoid convex pouching systems; if this isn't possible, use these systems with extreme caution. If the patient irrigates the colostomy, an ostomy management specialist should advise the patient to discontinue irrigation until the parastomal hernia resolves.<br>Surgery may be considered in extreme cases eg strangulation or obstruction or when the hernia affects the seal between the skin and appliance causing leakage. Other reasons may be if the hernia is causing a lot of pain or embarrassment to the ostomate, |
| **Reference** | |
| Dr Khalid/Rabia | Rabia |

| | |
|---|---|
| **Q: 8** | A man undergoes a pneumonectomy. After surgery, invs show hyponatremia. What could be the cause of the biochemical change?<br><br>a. Removal of hormonally active tumor<br>b. Excess dextrose<br>c. Excess colloid<br>d. Excessive K+<br>e. Hemodilution |
| | |

| **Clincher(s)** | **Pneumonectomy, Hyponatremia** |
|---|---|
| A | SIADH causes Hyponatraemia - removal of that hormone? (removal of small cell carcinoma..which produces ADH) |
| B | Excess dextrose can cause Na to move into cells – bloodstream Na decrease |
| C | Excess Colloid (gelatin of fresh blood) – can also be cause (volume expander) |
| D | |
| E | Hemodilution – can also be the cause |
| **KEY C/E** | **C/A? (confusion in skype)- should be A (SIDAH)** |
| Additional Information | Bad recall, same question came in NOV 5 exam … 'patient suffered massive hemorrhage intraoperative and post operation 48 hrs developed HYPONATREMIA. > then C |
| **Reference** | OHCM 170 |
| Dr Khalid/Rabia | Small cell lung carcinoma produces acth like peptide which stimulates aldosterone secretion causing hypernatremia. Removal of that will lead to hyponatremia.<br>OHCM 170...Lung tumors may secrete both ACTH and ADH. If it was an ACTH secreting tumor, then it's removal may cause hyponatremia. As ACTH helps in absorption of Na and water by releasing Aldosterone from adrenal gland. On the other hand, if it was an SIADH secreting tumor then opposite would happen. |

| **Q: 39** | A lady presents with itching around the breast and greenish foul smelling discharge from the nipple. She had a similar episode before. What is the most likely dx?<br><br>a. Duct papilloma<br>b. Duct ectasia<br>c. Breast abscess<br>d. Periductal mastitis<br>e. Mammary duct fistula |
|---|---|
| | |
| **Clincher(s)** | **Greenish discharge from nipple** |
| A | Local areas of epithelial proliferation in large mammary duct. May present with blood stained discharge. |
| B | Dilatation of the large breast ducts Most common around the menopause May present with a tender lump around the areola +/- a green nipple discharge. If ruptures may cause local inflammation, sometimes referred to as 'plasma cell mastitis' |
| C | More common in lactating women Red, hot tender swelling purulent discharge. |
| D | **Periductal mastitis** occurs when the ducts under the nipple become inflamed and infected. It's a benign condition (not cancer), which can affect women of all ages but is more common in younger women. Symptoms include: the breast becoming tender and hot to the touch. the skin may appear reddened. |
| E | **Mammary duct fistula**This is a communication between the skin and a major subareolar breast duct. It may occur following incision and drainage of a non-lactating abscess, spontaneous discharge of a periareolar mass or following biopsy of a |

| | |
|---|---|
| | periductal inflammatory mass. Treatment is by excision under antibiotic cover. |
| **KEY B** | **Duct Ectasia** |
| Additional Information | **Nipple discharge**<br>*Causes:* Duct ectasia (green/brown/red, often multiple ducts and bilateral), intraductal papilloma/adenoma/carcinoma (bloody discharge, often single duct), lactation. *Management:* Diagnose the cause (mammogram, ultrasound, ductogram); then treat appropriately. Cessation of smoking reduces discharge from duct ectasia. Microdochectomy/total duct excision can be considered if other measures fail, though may give no improvement in symptoms.<br><br>**Benign breast disease**[91]<br>*Fibroadenoma:* Usually presents <30yrs but can occur up to menopause. Benign overgrowth of collagenous mesenchyme of one breast lobule. Firm, smooth, mobile lump. Painless. May be multiple. ⅓ regress, ⅓ stay the same, ⅓ get bigger. ℞: Observation and reassurance, but if in doubt refer for USS (usually conclusive) ± FNA. Surgical excision if large.<br>*Breast cysts:* Common >35yrs, esp. perimenopausal. Benign, fluid-filled rounded lump. Not fixed to surrounding tissue. Occasionally painful. ℞: Diagnosis confirmed on aspiration (perform only if trained).<br>*Infective mastitis/breast abscesses:* Infection of mammary duct often associated with lactation (usually *S. aureus*). Abscess presents as painful hot swelling of breast segment. ℞: Antibiotics. Open incision or percutaneous drainage if abscess.<br>*Duct ectasia:* Typically around menopause. Ducts become blocked and secretions stagnate. Present with nipple discharge (green/brown/bloody) ± nipple retraction ± lump. Refer for confirmation of diagnosis. Usually no ℞ needed.<br>*Fat necrosis:* Fibrosis and calcification after injury to breast tissue. Scarring results in a firm lump. Refer for triple assessment. No ℞ once diagnosis confirmed. |
| **Reference** | OHCM 605 & 66 |
| Dr Khalid/Rabia | Q. 1. What is the key?<br>Q. 2. What other options (breast conditions) frequently come in plab mcq?<br>Ans. 1. Key is b.<br>Ans. 2. 1. **Breast ca 2. Duct papilloma and intraductal papilloma (both are same thing) 3. Mammary duct fistula 4. Breast abscess.** |

| | |
|---|---|
| **Q: 44** | A 50yo pt is admitted for elective herniography. Which of the following options will lead to a postponement of the operation?<br><br>a. SBP 110mmHg<br>b. MI 2 months ago<br>c. Hgb 12g/dl<br>d. Pain around hernia<br>e. Abdominal distention |

| | |
|---|---|
| | |
| | |
| **Clincher(s)** | |
| A | Spontaneous Bacterial Peritonitis |
| B | |
| C | |
| D | |
| E | |
| **KEY B** | Post MI elective surgery should not be done before 6 months. Recent MI increase risk of MI post operative. |
| Additional Information | (see in Samson notes/preoperative assessment) After 6 months of MI, can go for non cardiac surgery (herniography) |
| **Reference** | |
| Dr Khalid/Rabia | Key is B. After MI elective surgery should not be done before 6 months post MI.<br>Criteria for postponing elective surgery. ...Hb <10 ,<br>Plt count <50000<br>Systolic BP... <90<br>Uncontrolled HTN, DM , asthma<br>MI within 3 months |

| | |
|---|---|
| **Q: 92** | A man has reducible bulge below the pubic tubercle, and on occlusion of the deep inguinal ring, cough impulse is present. What is the most likely dx?<br><br>a. Direct inguinal<br>b. Indirect inguinal<br>c. Femoral<br>d. Spigelian<br>e. Lumbar |
| | |
| **Clincher(s)** | **Bulge below pubic tubercle** |
| A | |
| B | |
| C | Femoral hernia |
| D | |
| E | |
| **KEY B wrong: should be B** | **Femoral hernia → it is just below the pubic tubercle which is just below the inguinal ligament. (has nothing in relation to deep inguinal ring)**<br><br>**Should be indirect inguinal** |
| Additional Information | bad recall: hernia below pubic tubercle is femoral and **Cough impulse felt in occluded deep ring** is seen in **inguinal hernia.** In **Femoral Hernia positive cough impulse in femoral ring.**<br><br>Features of FEMORAL HERNIA: |

| | |
|---|---|
| | It is below and lateral to the PUBIC TUBERCLE.<br>More common in women, particularly multiparous ones.<br>High risk of obstruction and strangulation.<br> 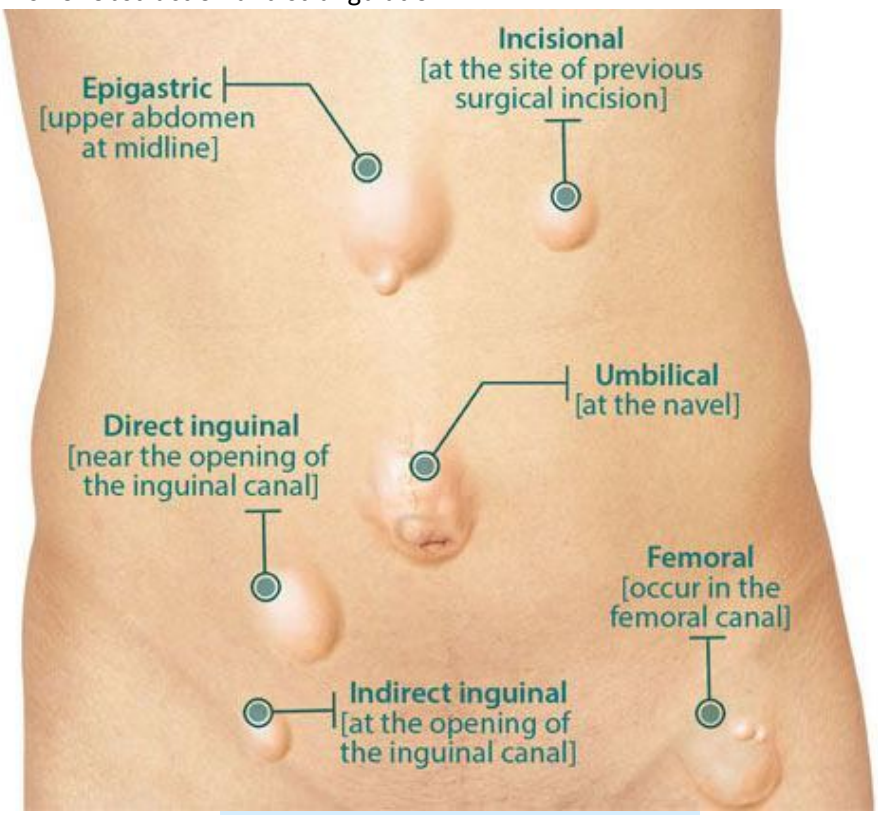 <br><br> 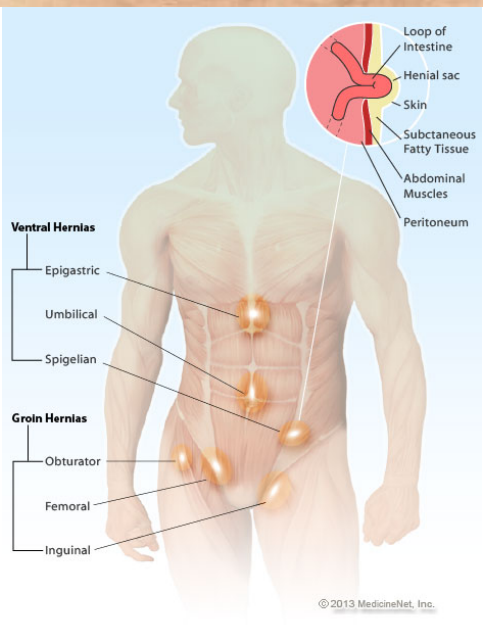 <br> |

## 614 Hernias

Surgery

**Definition** *The protrusion of a viscus or part of a viscus through a defect of the walls of its containing cavity into an abnormal position. Terminology:* Hernias involving bowel are said to be **irreducible** if they cannot be pushed back into the right place. This does not mean that they are either necessarily obstructed or strangulated. **Incarceration** implies that the contents of the hernial sac are stuck inside by adhesions. Gastrointestinal hernias are **obstructed** if bowel contents cannot pass through them—the classical features of intestinal obstruction soon appear (p612). They are **strangulated** if ischaemia occurs—the patient becomes toxic and requires urgent surgery. Care must be taken when attempting reduction (see p616 for the technique) as it is possible to perform **reduction** *en masse*, pushing the strangulated bowel and hernial sac back into the abdominal cavity, but giving the initial appearance of successful reduction.

**Inguinal hernia** The commonest type (far more common in men), described on p616.

**Femoral hernia** Bowel enters the femoral canal, presenting as a mass in the upper medial thigh or above the inguinal ligament where it points down the leg, unlike an inguinal hernia which points to the groin. They occur more often in women especially in middle age and the elderly. They are likely to be irreducible and to strangulate due to the rigidity of the canal's borders. *Anatomy:* The neck of the hernia is felt inferior and lateral to the pubic tubercle (inguinal hernias are superior and medial to this point). The boundaries of the femoral canal are anteriorly the inguinal ligament; medially the lacunar ligament (and pubic bone); laterally the femoral vein (and iliopsoas); and posteriorly the pectineal ligament and pectineus. The canal contains fat and Cloquet's node. *Differential diagnosis:*[108] (see also p653) **1** Inguinal hernia **2** Saphena varix **3** An enlarged Cloquet's node (p619) **4** Lipoma **5** Femoral aneurysm **6** Psoas abscess. *Treatment:* Surgical repair is recommended. (*Herniotomy* is ligation and excision of the sac, *herniorrhaphy* is repair of the hernial defect.)

**Paraumbilical hernias** occur just above or below the umbilicus. Risk factors are obesity and ascites. Omentum or bowel herniates through the defect. Surgery involves repair of the rectus sheath (Mayo repair).

**Epigastric hernias** pass through linea alba above the umbilicus.

**Incisional hernias** follow breakdown of muscle closure after surgery (11-20%). If obese, repair is not easy. Mesh repair has ↓recurrence but ↑infection over sutures.[109]

**Spigelian hernias** occur through the linea semilunaris at the lateral edge of the rectus sheath, below and lateral to the umbilicus.

**Lumbar hernias** occur through the inferior or superior lumbar triangles in the posterior abdominal wall.

**Richter's hernias** involve bowel wall only—not the whole lumen.

**Maydl's hernias** involve a herniating 'double loop' of bowel. The strangulated portion may reside as a single loop inside the abdominal cavity.

**Littre's hernias** are hernial sacs containing strangulated Meckel's diverticulum.

**Obturator hernias** occur through the obturator canal. Typically there is pain along the medial side of the thigh in a thin woman.

**Sciatic hernias** pass through the lesser sciatic foramen (a way through various pelvic ligaments). GI obstruction + a gluteal mass suggests this rare possibility.[110]

**Sliding hernias** contain a partially extraperitoneal structure (eg caecum on the right, sigmoid colon on the left). The sac does not completely surround the contents.

**Other examples of hernias:**

- Of the nucleus pulposus into the spinal canal (slipped disc).
- Of the uncus and hippocampal gyrus through the tentorium (tentorial hernia) in space-occupying lesions.
- Of brainstem and cerebellum through the foramen magnum (Arnold-Chiari, p708).
- Of the stomach through the diaphragm (hiatus hernia, p245).
- Of the terminal (intravesical) portion of the ureter into the bladder. This is a *ureterocele* and results from stenosis of the ureteral meatus.

## 616 Inguinal hernias

(*OHClinSurg* p320)

Indirect hernias pass through the internal inguinal ring and, if large, out through the

| **Reference** | OHCM 614/616 & Pass medicine |
|---|---|
| Dr Khalid/Rabia | |

| **Type of hernia** | **Details** |
|---|---|
| **Inguinal hernia** | Inguinal hernias account for 75% of abdominal wall hernias.<br>Around 95% of patients are male; men have around a 25% lifetime risk of developing an inguinal hernia.<br>Above and medial to pubic tubercle<br>Strangulation is rare |
| **Femoral hernia** | Below and lateral to the pubic tubercle<br>More common in women, particularly multiparous ones<br>High risk of obstruction and strangulation<br>Surgical repair is required |
| **Umbilical hernia** | Symmetrical bulge under the umbilicus |
| **Paraumbilical hernia** | Asymmetrical bulge - half the sac is covered by skin of the abdomen directly above or below the umbilicus |
| **Epigastric hernia** | Lump in the midline between umbilicus and the xiphisternum<br>Most common in men aged 20-30 years |

| | | |
|---|---|---|
| | **Incisional hernia** | May occur in up to 10% of abdominal operations |
| | **Spigelian hernia** | Also known as lateral ventral hernia<br><br>Rare and seen in older patients<br><br>A hernia through the spigelian fascia (the aponeurotic layer between the rectus abdominis muscle medially and the semilunar line laterally) |
| | **Obturator hernia** | A hernia which passes through the obturator foramen. More common in females and typical presents with bowel obstruction |
| | **Richter hernia** | A rare type of hernia where only the antimesenteric border of the bowel herniates through the fascial defect |

| | |
|---|---|
| **Q: 104** | A 50yo man has had anterior resection of the rectum for carcinoma. He expressed concerns about control of post-op pain in discussions with the anaesthetist before surgery. What is the best management strategy?<br><br>a. Oral diclofenac<br>b. Oral codeine<br>c. IM morphine<br>d. IM dihydrocodeine<br>e. Ondansetron oral |
| | |
| **Clincher(s)** | **Post Op Pain** |
| A | Oral route not suitable because underwent abdominal surgery. Most likely he will be NPO (Nill Per Os – withhold oral foods and fluids) |
| B | |

| | |
|---|---|
| C | Strong analgesic – patient also concerned about post op pain |
| D | Useful for mild to moderate pain |
| E | Anti-emetic (Ondansetron blocks the actions of chemicals in the body that can trigger nausea and vomiting. Ondansetron is not for preventing nausea or vomiting that is caused by factors other than cancer treatment or surgery.) |
| **KEY C** | **IM MORPHINE strong analgesic and most suitable for severe pain** |
| Additional Information | **The WHO analgesic ladder**[63] (See p576 for NNT)<br>Rung 1 *Non-opioid* Paracetamol; NSAIDs<br>Rung 2 *Weak opioid* Codeine; dihydrocodeine; tramadol<br>Rung 3 *Strong opioid* Morphine; diamorphine; hydromorphone; oxycodone; fentanyl; buprenorphine (± adjuvant analgesics)<br>Unlike other ladders this ladder is not used to fetch something out of reach—adequate pain relief should be attainable to all. If one drug fails to relieve pain, move up—do not try other drugs at the same level. In new, severe pain, rung 2 may be omitted.[64]<br>539 Oncology and palliative care<br>**Opiate dose equivalents**[65]<br>Morphine PO: 24h dose (mg) 30; 4h dose (mg) 5; Relative potency to oral morphine 1×<br>Morphine IV: 24h dose (mg) 15; 4h dose (mg) 2.5; Relative potency to oral morphine 2×<br>Morphine SC: 24h dose (mg) 15; 4h dose (mg) 2.5; Relative potency to oral morphine 2×<br>Diamorphine IV: 24h dose (mg) 12; 4h dose (mg) 2; Relative potency to oral morphine 3×<br>Diamorphine SC: 24h dose (mg) 12; 4h dose (mg) 2; Relative potency to oral morphine 3×<br>Oxycodone PO: 24h dose (mg) 15; 4h dose (mg) 2.5; Relative potency to oral morphine 2×<br>Oxycodone IV: 24h dose (mg) 12; 4h dose (mg) 2; Relative potency to oral morphine 3×<br>Oxycodone SC: 24h dose (mg) 7.5–15; 4h dose (mg) 1.25–2.5; Relative potency to oral morphine 3×<br>Alfentanil SC[1]: 24h dose (mg) 1; 4h dose (mg) —; Relative potency to oral morphine 30×<br>To convert oral codeine, dihydrocodeine, or tramadol to oral morphine, divide the total daily dose by about 10.<br>Conversions are not exact; these tables are intended as a rough guide. The potency figures in particular can vary widely. If in doubt, use a dose below your estimate. |
| **Reference** | OHCM 539 |
| Dr Khalid/Rabia | Oral route will not be suitable for this patient as he is having a major abdominal surgery so most probably he will be NPO post operatively. Dihydrocodeine is useful for mild to moderate pain but since its a major surgery and the patient is himself worried about the pain good analgesia should be maintained. Ondensetron is an anti emetic not an analgesic. So the most suitable option here is IM Morphine as it is a strong analgesic most suitable for severe pain. |

| | |
|---|---|
| **Q:1404** | 1404. A 23yo woman presents with a 1cm small smooth, firm, mobile mass in her left breast. She is very anxious. What is the most appropriate inv?<br>a. Mammography<br>b. US breast<br>c. FNAC |

| | |
|---|---|
| | d. Mammography and US |
| | |
| **Clincher(s)** | Young age |
| A | Is used as a screening tool in the UK for breast CA. |
| B | Used for lumps evaluation of lumps in a patient <35 years. |
| C | After USG in young and USG + mammography in >35 years |
| D | For adults >35 |
| **KEY** | b |
| Additional information | Fibroadenoma. Usually presents <30yrs but can occur up to menopause. Benign overgrowth of collagenous mesenchyme of one breast lobule. Firm, smooth, mobile lump. Painless. May be multiple.⅓regress, ⅓ stay the same, ⅓ get bigger. :Observa-tion and reassurance, but if in doubt refer for USS (usually conclusive) ± FNA Surgical excision if large<br><br>Triple assessment'<br>1 Clinical examination<br>2 Radiology: ultrasound for <35yrs; mammography and ultrasound for >35yrs old<br>3 Histology/cytology( FNA or core biopsy: US-guided core biopsy is best for new Lumps<br><br>Ref. ochm |

| | |
|---|---|
| **Q:1421** | A 30yo woman has a painless lump in the outer aspect of her left breast. She has had a prv breast lump. Her grandmother had breast cancer at 70yrs. She has a 1 cm smooth, firm, discrete, mobile lump in the other quadrant region of the left breast. What is the single most likely dx?<br>a. Breast abscess<br>b. Breast carcinoma<br>c. Breast cyst<br>d. Fibroadenoma<br>e. Sebaceous cyst |

| | |
|---|---|
| **Clincher(s)** | **Clinical assessment** |
| A | **Infection of mammaory duct often associated with lactation ( usually staph aureus ) infection presents as painful hot swelling of breast segment. Tx antibiotic. Open incision or percutaneous drainage of abcess.** |
| B | Painless. Hard gritty feeling. Mobile or attached to the structures and chest wall depending upon the stage. Irreguler and ill defined mass. May or may not be associated with nipple abnormalities like changes in the shape of the nipple( inverted everted or destroyed ) and bloody discharge. Skin changes, dimpling, puckering, color changes and pudeb orange appearance due to lumphodema that shows involvement of lumphnodes. Systemic features, anorexia, weight loss, and signs of involvement of organs due to metastasis. |
| C | Common >35 years specially perimenopausal. Benign, fluid filled rounded lump. Not fixed to surrounding structures. Occasionally painful. Diagnosis confirmed on aspiration. |
| D | **Fibroadenoma. Usually presents <30yrs but can occur up to menopause. Benign overgrowth of collagenous mesenchyme of one breast lobule. Firm, smooth, mobile lump. Painless. May be multiple.⅓regress, ⅓ stay the same, ⅓ get bigger** |
| E | **Subaceous glands secretes oily secretions that come up through ducts, if those ducts are blocked, subaceous cysts can develop. Common sites face, neck and trunk. If they get infected they become painful. Treatment if large, drainage and antibiotics. Central punctum will be present, more superficial and cyst will be more deeper.** |
| **KEY** | **D** |
| Additional information | **Treatment of breast CA.**<br>**Hormone therapy ( temoxifine for premenopausal and letrozole for postmenopausal women ), in estrogen receptor positive patients plus Surgery for localized disease.**<br>**Chemotherapy plus hormone therapy plus radiotherapy for metastatic disease. Surgery can only be done locally for symptomatic control like fungating tumor in advanced diseases.**<br>**Radiotherapy for metastasis** |

| | |
|---|---|
| **Q:1425** | . A 35yo woman complains of hoarseness of voice 3h after partial thyroidectomy. She |

| | |
|---|---|
| | had no hx of phonation problems before the surgery. What is the single most appropriate inv?<br>a. Laryngoscopy<br>b. Bronchoscopy<br>c. CT neck<br>d. CXR<br>e. Barium swallow |
| | |
| **Clincher(s)** | **Problem of vocal cord after partial thyroidectomy.** |
| A | **Can be used to detect the problem of lyranx and vocal cords** |
| B | Vocal cords can be seen but it is usually used to see different divisions of bronchi. |
| C | Cannot be diagnostic in this case (Staging or rule out neck structure cancers- except nose) |
| D | **Cannot be diagnostic** |
| E | **Cannot be diagnostic** |
| **KEY** | **A** |
| Additional information | Complications These are usually very few. Remove the drain the next day and discharge the patient.The important structures that must be considered when operating on the thyroid gland include<br><br>• Recurrent laryngeal nerve.( branch of vagus nerve which supplies all the intrinsic muscles of the larynx except cricothyroid muscle. These muscles act to open and close the vocal cords.<br><br>• Superior laryngeal nerve.<br><br>• Parathyroid glands.<br><br>• Trachea.<br><br>• Common carotid artery.<br><br>• Internal jugular vein (not depicted).<br><br>Management Common indications Contraindications Disadvantages/complications **Antithyroid** drugs (carbimazole, propylthiouracil) First episode in patients < 40 yrs Breastfeeding (propylthiouracil suitable)<br><br>SE:Hypersensitivity rash 2% Agranulocytosis 0.2% > 50% relapse rate usually within 2 years of stopping drug<br><br>**Subtotal thyroidectomy**<br><br>INDICATION::Large goitre Poor drug compliance, especially in young patients Recurrent thyrotoxicosis after course of antithyroid drugs in young patients |

| | |
|---|---|
| | CI: Previous thyroid surgery Dependence upon voice, e.g. opera singer, lecturer<br><br>SE:1 Hypothyroidism (^25%) Transient hypocalcaemia (10%) Permanent hypoparathyroidism (1%) Recurrent laryngeal nerve palsy1 (1%<br><br>**Radio-iodine Patients**<br><br>INDICATION > 40 yrs2 Recurrence following surgery irrespective of age<br><br>CI:Other serious comorbidity Pregnancy or planned pregnancy within 6 months of treatment Active Graves' ophthalmopathy<br><br>SE3 Hypothyroidism, ^40% in first year, 80% after 15 years Most likely treatment to result in exacerbation of ophthalmopathy3<br><br>1 It is not only vocal cord palsy due to recurrent laryngeal nerve damage which alters the voice following thyroid surgery; the superior laryngeal nerves are frequently transected and result in minor changes in voice quality. 2 In many institutions, 131I is used more liberally and prescribed for much younger patients. 3 The extent to which radio-iodine exacerbates ophthalmopathy is controversial and practice varies; some use prednisolone for 4 months to reduce this risk. |

| **Q:1566** | A woman is admitted to the hospital for elective abdominal hysterectomy. 2 months ago she was dx with DVT and pulmonary embolism and was started on warfarin. What is the most appropriate pre-op measure you will take on this occasion?<br>a. Continue warfarin<br>b. Stop warfarin<br>c. Stop warfarin and start heparin<br>d. Increase warfarin dose<br>e. Add heparin |
|---|---|
| | |
| **Clincher(s)** | **Excluding other options** |
| A | **Difficult to reverse.** |
| B | Should be on some anticoagulant |
| C | Because heparin has less half life and can be reversed quickly |
| D | **Narrow therapeutic index** |
| E | **No need to give two anticoagulants apart from initial period.** |
| **KEY** | **C** |

| | |
|---|---|
| Additional information | **Hepari1** Low molecular weight heparin (LMWH) Given sc. Molecular weight ~5000 Daltons (Da), eg dalteparin, enoxaparin, tinzaparin. Inactivates factor Xa (but not thrombin). T ½ is 2- to 4-fold longer than standard heparin, and response is more predictable, and so only needs to be given once or twice daily, and no laboratory monitoring is usually required. It has replaced unfractionated heparin (UFH) as the preferred option in the prevention and treatment of venous thromboembolism and in acute coronary syndrome. It accumulates in renal failure: lower doses are used for prophylaxis, or UFH for therapeutic doses.<br>**2** Unfractionated heparin (UFH)IV or SC. 13000Daltons. A glycosaminoglycan, which binds antithrombin (an endogenous inhibitor of coagulation), increasing its ability to inhibit thrombin, factor Xa, and IXa. Rapid onset and has a short T ½Monitor and adjust dose with APTT.<br>SE for both:<br>\|<br>Bleeding (eg at operative site, gastrointestinal, intracranial), heparin-induced thrombocytopenia (HIT), osteoporosis with long-term use. HIT and osteo-<br>porosis are less common with LMWH than UFH Beware hyperkalaemia.<br>CI Bleeding disorders, platelets <60≈109/L, previous HIT peptic ulcer, cerebral haemorrhage, severe hypertension, neurosurgery.<br>**Warfarin**<br>is used orally once daily as long-term anticoagulation. The therapeutic range is narrow, varying with the condition being treated.<br>and is measured as a ratio compared with the standard INRWarfarin inhibits the reduc-<br>tase enzyme responsible for regenerating the active form of vitamin Kproducing a state analogous to vit K deficiency.<br>CI<br>:Peptic ulcer, bleeding disorders, severe hy-pertension, pregnancy (teratogenic, see OHCSp 640). Use with caution in the elderly and those with past GIbleeds. In the UK , warfarin tablets are 0.5mg (white), 1mg(brown), 3mg (blue), or 5mg (pink).<br>.<br><br>**DURATION OF ANICOAGULATION IN DVT/ PE**<br><br>**. if cause will go away ( post operative cases)**<br><br>**Atleast 6 weeks for below knee dvt**<br><br>**Atleast 3 months for above knee dvt and PE**<br><br>**Atleast 6 months if no cause is found**<br><br>**Indefinitely for identified, enduring causes eg, thrombophilia.** |

| | |
|---|---|
| **Q:1634** | 1634. A 65yo man had closure of colostomy performed 5d ago. He is not systemically |

| | |
|---|---|
| | unwell. There is a tender, localised fluctuant swelling 4 cm in diameter in the wound. What is the SINGLE most appropriate management?<br>a. Abdominal support<br>b. Antibiotics<br>c. Laparotomy and re-suture wound<br>d. Local exploration of wound<br>e. Observation |
| | |
| **Clincher(s)** | **Swelling at the local site and systemically well.** |
| A | **NO, Because pathology needs to be ruled out.** |
| B | Can be given in the initial stage of infection when there are signs of inflammation without pus formation, afterwards drainage. |
| C | Laparotomy should only be done if the signs of peritonitis are there. |
| D | **Should be done to evaluate the cause** |
| E | **Cannot be done** |
| **KEY** | **d** |
| Additional information | Credit goes to dr Zohaib.<br><br>The most common local complication of stoma is abscess formation and whenever you examine post operative patient with colostomy with fluctuation, redness and fever, always think abscess.<br><br>Other complications of colostomies.<br><br>Prolapse<br>Retraction<br>Necrosis of the distal end<br>Fistula formation<br>Stenosis of the orifice<br>Colostomy hernia<br>Bleeding<br>Colostomy diarrhoea |

| | |
|---|---|
| **Q:** | 1523. A 63yo male undergoes abdominal surgery. On Monday morning, 3d post-op, repeat samples confirm serum K+=7.1mmol/l. His ECG shows broad QRS complexes. Which one of the following can be used as an effective tx for this pt's hyperkalemia?<br>a. Calcium chloride IV |

| | |
|---|---|
| | b. Calcium gluconate IV<br>c. Insulin subcutaneously<br>d. Furosemide IV |
| | |
| **Clincher(s)** | **Abdominal surgery,K 7.1mmol/l,ECG,broad QRS complexes** |
| A | Usually used in patients with hypocalcemia |
| B | |
| C | Insulin Sc is also used for tx of hyperkalemia but as supportive(not the 1st line)aids to shift potassium intracellularly,should be used in caution in diabetics |
| D | Furosemide iv,although would increase potassium excretion but it will also lead to hyponatremia. |
| E | |
| **key** | **B** |
| Additional Information | Hyperkalemia:<br>Causes<br>• Oliguric renal failure<br>• K+-sparing diuretics<br>• Rhabdomyolysis (p307)<br>• Metabolic acidosis (DM)<br>• Excess K+ therapy<br>• Addison's disease (see p218)<br>• Massive blood transfusion<br>• Burns<br>• Drugs, eg ACE-i, suxamethonium<br>•**signs and symptoms** include a fast irregular pulse, chest pain, weakness,palpitations, and light-headedness. ECG: (see ECG 9) tall tented T waves, small Pwaves, a wide QRS complex (eventually becoming sinusoidal), and ventricular fibrillation<br><br>Management:<br>Acute severe hyperkalaemia (plasma-potassium concentration above 6.5 mmol/litre or in the presence of ECG changes) calls for urgent treatment with 10–20mL of calcium gluconate 10% by slow intravenous injection, titrated and adjusted to ECG improvement, to temporarily protect against myocardial excitability. An intravenous injection of soluble insulin (5–10 units) with 50mL glucose 50% given over 5–15 minutes, reduces serum-potassium concentration; this is repeated if necessary or a continuous infusion instituted, Salbutamol [unlicensed indication], by nebulisation or slow intravenous injection may also reduce plasma-potassium concentration; it should be used with caution in |

| | |
|---|---|
| | patients with cardiovascular disease. The correction of causal or compounding acidosis with sodium bicarbonate infusion (section 9.2.2) should be considered (important: preparations of sodium bicarbonate and calcium salts should not be administered in the same line—risk of precipitation). Drugs exacerbating hyperkalaemia should be reviewed and stopped as appropriate; occasionally haemodialysis is needed.<br>Ion-exchange resins may be used to remove excess potassium in mild hyperkalaemia or in moderate hyperkalaemia when there are no ECG changes.<br>**Hyperkalaemia**<br>The danger is ventricular fibrillation. $K^+$ >7.0mmol/L requires urgent treatment, as does $K^+$ >6mmol/L or potentially lower values if there are ECG changes:<br>• Tall 'tented' T waves ± flat P waves ± increased PR interval (p. 688, ECG p. 689).<br>• Widening of the QRS complex—leading eventually, and dangerously, to a sinusoidal pattern and VF/VT.<br> 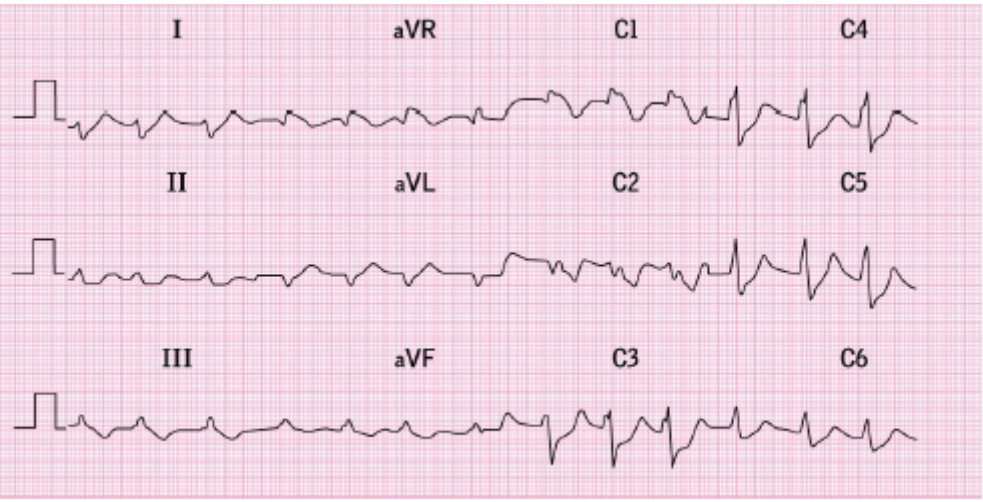 <br><br>ECG 9. Hyperkalaemia—note the flattening of the P waves, prominent T waves, and widening of the QRS complex. |
| **Reference** | BNF page 666,ohcm page 688,948 |

| | |
|---|---|
| **Q:1524** | 1524. A 25yo man attended in urological OPD has single testis. He was inv and other testis was located in the abdomen. What is the best management plan for this pt?<br>a. Short trial of HCG<br>b. Orchidectomy (25yr)<br>c. Orchidopexy (< 1 yar old)<br>d. Reassurance |
| | |

| **Clincher(s)** | **Age,testes located in abdomen** |
|---|---|
| A | Hormonal treatment not given anymore due to many side effects like enlargement of genitalia,pubic hair growth, |
| B | |
| C | If truly undescended it will lie along<br>the path of descent from the abdominal cavity. Early (eg at 1 year) fi xing within the scrotum (orchidopexy) may prevent infertility and reduces later neoplasia (untreated, risk is >5-fold). |
| D | Not sufficient |
| E | |
| **KEY** | **B** |
| Additional Information | |
| **Reference** | OHCM |

| **Q:1531** | In a laparoscopic mesh repair for hernia, when the trocar is inserted at midpoint between<br>umbilicus and ischial spine. What structure will be pierced?<br>a. Linea alba<br>b. Rectus muscle<br>c. Conjoint tendon<br>d. External and internal oblique muscles<br>e. Inguinal ligament |
|---|---|
| | |
| **Clincher(s)** | **Mesh repair,location** |
| A | |
| B | |
| C | The **conjoint tendon** forms when the medial fibres of the internal oblique aponeurosis unite with the deeper fibres of the transversus abdominis aponeurosis. The conjoint tendon then urns inferiorly tand attaches onto the pubic crest and pecten pubis [1]. It forms part of the posterior wall of the inguinal canal. |
| D | Answer: D<br>Structures in Anterior Abdominal Wall<br>In human anatomy, the layers of the abdominal wall are (from superficial to deep):<br>Skin<br>Subcutaneous tissue<br>Fascia<br>Camper's fascia - fatty superficial layer.<br>Scarpa's fascia - deep fibrous layer.<br>Muscle<br>External oblique muscle<br>Internal oblique muscle<br>Rectus abdominis<br>Transverse abdominal muscle |

| | |
|---|---|
| | Pyramidalis muscle<br>Fascia transversalis<br>Peritoneum |
| E | |
| **KEY** | **D** |
| Additional Information | 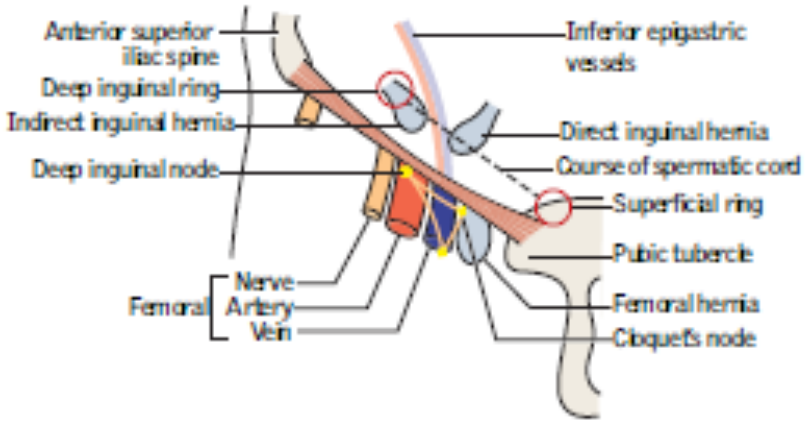 <br><br>Fig 1. Anatomy of the inguinal canal.<br><br>**The contents of the inguinal canal in the male**<br>• The external spermatic fascia (from external oblique), cremasteric fascia (from internal oblique and transverses abdominus) and internal spermatic fascia (from transversalis fascia) covering the cord.<br>• The spermatic cord:<br>  • Vas deferens, obliterated processus vaginalis, and lymphatics<br>  • Arteries to the vas, cremaster, and testis<br>  • The pampiniform plexus and the venous equivalent of the above<br>  • The genital branch of the genitofemoral nerve and sympathetic nerves<br>• The ilioinguinal nerve, which enters the inguinal canal via the anterior wall and runs anteriorly to the cord.<br>NB: in the female the round ligament of the uterus is in place of the male structures. A hydrocele of the canal of Nuck is the female equivalent of a hydrocele of the cord. |

## Inguinal hernias

(OHClinSurg p320)

**Indirect** hernias pass through the internal inguinal ring and, if large, out through the external ring. **Direct** hernias push their way *directly* forward through the posterior wall of the inguinal canal, into a defect in the abdominal wall (Hesselbach's triangle; medial to the inferior epigastric vessels and lateral to the rectus abdominus). *Predisposing conditions:* males (♂:♀≈8:1), chronic cough, constipation, urinary obstruction, heavy lifting, ascites, past abdominal surgery (eg damage to the iliohypogastric nerve during appendicectomy). There are 2 landmarks to identify: *The deep (internal) ring* may be defined as being the **mid-point of the inguinal ligament**, ~1½ cm above the femoral pulse (which crosses the **mid-inguinal point**). *The superficial (external) ring* is a split in the external oblique aponeurosis just superior and medial to the pubic tubercle (the bony prominence forming the medial attachment of the inguinal ligament). Relations of the inguinal canal are:

- *Floor:* Inguinal ligament and lacunar ligament medially.
- *Roof:* Fibres of transversalis, internal oblique.
- *Anterior:* External oblique aponeurosis + internal oblique for the lateral ⅓.
- *Posterior:* Laterally, transversalis fascia; medially, conjoint tendon.

**Examination** Look for previous scars; feel the other side (more common on the right); examine the external genitalia. Then ask: •Is the lump visible? If so, ask the patient to reduce it—if he cannot, make sure that it is not a scrotal lump. Ask him to cough. Appears **above and medial to the pubic tubercle**. •If no lump is visible, feel for a cough impulse. •Repeat the examination with the patient standing. *Distinguishing direct from indirect hernias:* This is loved by examiners but is of little clinical use—not least because repair is the same for both (see below). The best way is to reduce the hernia and occlude the deep (internal) ring with two fingers. Ask the patient to cough or stand—if the hernia is restrained, it is indirect; if not, it is direct. The 'gold standard' for determining the type of inguinal hernia is at surgery: direct hernias arise lateral to the inferior epigastric vessels; indirect hernias are medial.

| Indirect hernias: | Direct hernias: | Femoral hernias: |
|---|---|---|
| • Common (80%)<br>• Can strangulate | • Less common (20%)<br>• Reduce easily<br>• Rarely strangulate | • More frequent in females<br>• Frequently irreducible<br>• Frequently strangulate |

**Femoral hernia** Bowel enters the femoral canal, presenting as a mass in the upper medial thigh or above the inguinal ligament where it points down the leg, unlike an inguinal hernia which points to the groin. They occur more often in women especially in middle age and the elderly. They are likely to be irreducible and to strangulate due to the rigidity of the canal's borders. *Anatomy:* The neck of the hernia is felt inferior and lateral to the pubic tubercle (inguinal hernias are superior and medial to this point). The boundaries of the femoral canal are anteriorly the inguinal ligament; medially the lacunar ligament (and pubic bone); laterally the femoral vein (and iliopsoas); and posteriorly the pectineal ligament and pectineus. The canal contains fat and Cloquet's node. *Differential diagnosis:*[108] (see also p653) 1 Inguinal hernia 2 Saphena varix 3 An enlarged Cloquet's node (p619) 4 Lipoma 5 Femoral aneurysm 6 Psoas abscess. *Treatment:* Surgical repair is recommended. (*Herniotomy* is ligation and excision of the sac, *herniorrhaphy* is repair of the hernial defect.)

| | |
|---|---|
| **Reference** | OHCM 614,616(all about hernias) |

| | |
|---|---|
| **Q:1538** | 1538. A 2yo fell on outstretched hand on playground. He presents with pain on base of the thumb. XR=no fx. What is the single most likely dx?<br>a. Colles fx |

| | |
|---|---|
| | b. Head of radius<br>c. Mellet finger<br>d. Scaphoid fx<br>e. No fx |
| | Fall on outstretched hand,XRay no fracture |
| **Clincher(s)** | |
| A.Colles fracture | The classical definition is a fracture through the distal metaphysis of the radius, approximately 4 cm proximal to the articular surface. The term is now more loosely used for any fracture of the distal radius, with or without involvement of the ulna, with dorsal (backward) displacement of the fracture fragments.<br> |
| B | |
| C | A mallet finger is where the end of a finger is bent (flexed) towards the palm and cannot straighten.It is **extensor tendon injury**, is an injury of the extensor digitorum tendon of the fingers at the distal interphalangeal joint (DIP).[2] It results from hyperflexion of the extensor digitorum tendon, and usually occurs when a ball (such as a softball, basketball, volleyball or dodgeball), while being caught, hits an outstretched finger and jams it, creating a ruptured or stretched extensor digitorum tendon..<br> 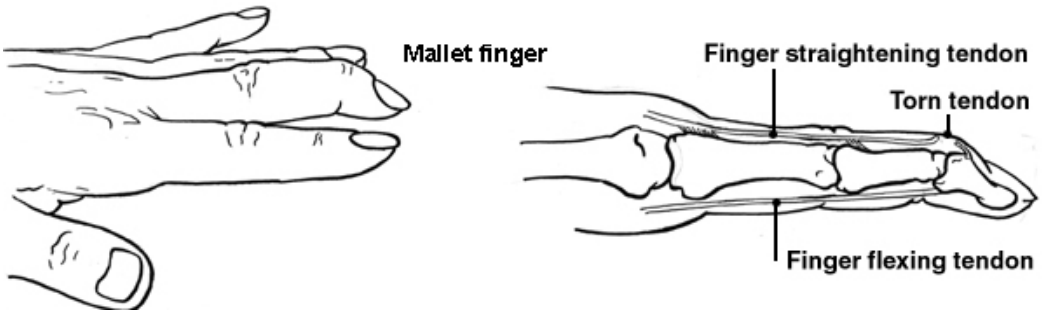 |
| D | |

| | |
|---|---|
| E | |
| **KEY** | **D** |
| Additional Information | The scaphoid bone is one of the carpal bones in your hand around the area of your wrist. It is the most common carpal bone to break (fracture). A scaphoid fracture is usually caused by a fall on to an outstretched hand. Symptoms can include pain and swelling around the wrist. Treatment is usually with a cast worn on your arm up to your elbow for 8 to 12 weeks. Sometimes surgery is advised. Correct diagnosis and prompt treatment of a scaphoid fracture can help to reduce complications.<br>**Scaphoid fracture** Common and easily missed on radiography; results from falls on the hand. *Signs:* Tender in anatomical snuff box and over scaphoid tubercle, pain on axial compression of the thumb, and on ulnar deviation of the pronated wrist, or supination against resistance. *Imaging:* Request a dedicated 'scaphoid' series. If -ve, and fracture is suspected MRI has been shown to be sensitive and cost-effective.[270] CT is an alternative. If neither is available, cast and re-x-ray in 2 weeks. Nondisplaced fractures involving the waist may be immobilized in a neutral forearm cast for several weeks until union. Percutaneous cannulated screw fixation allows the patient to return to work earlier but does not affect the long-term outcome.[271] *Complications:* Avascular necrosis: the proximal pole relies on interosseous supply from the distal part. |
| **Reference** | OHCS,744,dr Rabia notes |

| | |
|---|---|
| **Q:1543** | A lady with post ileocolectomy closure of stoma has a small 4 cm swelling around the stoma. What is the most appropriate management of the swelling?<br>a. Local exploration of swelling<br>b. Exploratory laparotomy<br>c. Open laparotomy and re-closure<br>d. Abdominal binder<br>e. Truss<br>f. Laparotomy with mesh repair |
| | |
| **Clincher(s)** | **Post ileocolectomy closure,swelling around stoma** |
| A | Could be A..not sure though. |
| B | No indication |
| C | |
| D | |
| E | kind of surgical appliance,partuclarly used for hernia patients |
| **KEY** | **D** |
| Additional Information | Most hernias can be managed without surgery. Support belts and appliances are the most successful aids. These are available on prescription in the UK)<br>Parastomal hernia<br>A parastomal hernia involves an ostomy in the area where the stoma exits the abdominal cavity. The intestine or bowel extends beyond the abdominal cavity |

| | |
|---|---|
| | or abdominal muscles; the area around the stoma appears as a swelling or protuberance. Parastomal hernias are incisional hernias in the area of the abdominal musculature that was incised to bring the intestine through the abdominal wall to form the stoma. They may completely surround the stoma (called circumferential hernias) or may invade only part of the stoma.<br>Parastomal hernias can occur any time after the surgical procedure but usually happen within the first 2 years. Recurrences are common if the hernia needs to be repaired surgically. Risk factors may be patient related or technical. Patient-related risk factors include obesity, poor nutritional status at the time of surgery, presurgical steroid therapy, wound sepsis, and chronic cough. Risk factors related to technical issues include size of the surgical opening and whether surgery was done on an emergency or elective basis.<br>Parastomal hernias occur in four types. Initially, a parastomal hernia begins as an unsightly distention in the area surrounding the stoma; the hernia enlarges, causing pain, discomfort, and pouching problems resulting in peristomal skin complications that require frequent assessment. Conservative therapy is the usual initial treatment. Adjustments to the pouching system typically are required so changes in the shape of the pouching surface can be accommodated. Also, a hernia support binder or pouch support belt may be helpful. Avoid convex pouching systems; if this isn't possible, use these systems with extreme caution. If the patient irrigates the colostomy, an ostomy management specialist should advise the patient to discontinue irrigation until the parastomal hernia resolves.<br>Surgery may be considered in extreme cases eg strangulation or obstruction or when the hernia affects the seal between the skin and appliance causing leakage. Other reasons may be if the hernia is causing a lot of pain or embarrassment to the ostomate |
| **Reference** | Dr Rabia notes |

| | |
|---|---|
| **Q: 198** | A 60yo pt recovering from a surgery for toxic goiter is found to be hypotensive, cyanosed in the the RR. Exam: tense neck. There is blood oozing from the drain (hge from surgical site). What is the most likely dx?<br>a. Thyroid storm (if ebdo organ is removed- sudden compensatory reaction to normalize hemostatic- falling BP, - no other signs)<br>b. Reactionary hemorrhage (<24 hr- slip of ligature, dislodgment of plug, uncontrolled HTN))<br>c. Secondary hemorrhage (7-14 days- infection)<br>d. Primary hemorrhage (primary- op table)<br>e. Tracheomalacia |
| | |
| **Clincher(s)** | |
| A | There is hypertension in thyroid storm.<br>Thyroid storm is a life-threatening health condition that is associated with untreated or undertreated hyperthyroidism. During thyroid storm, an individual's heart rate, blood pressure, and body temperature can soar to dangerously high levels. Without prompt, aggressive treatment, thyroid storm is often fatal. |

| | |
|---|---|
| | Thryroid storm is a diagniostic probability after thyroidal or noin thryroidal surgery, but in this case scenario, the clinical presentation fits reactionary hemorrhage. |
| B | |
| C | Secondary hemorage occurs after 7-14 days |
| D | **Primary hemorage occurs at the time of surgery** |
| E | **Tracheomalacia** (from trachea and the Greek μαλακία, softening) is a condition characterized by flaccidity of the tracheal support cartilage which leads to tracheal collapse especially when increased airflow is demanded. The trachea normally dilates slightly during inspiration and narrows slightly during expiration. |
| **KEY** | The key is B. Reactionary haemorrhage. [in the recovery room, cyanosis, hypotension, tense neck, oozing of blood from drain; all these goes in favour of reactionary haemorrhage]. |
| Additional Information | **Primary Haemorrhage:** Haemorrhage occurring at the time of Injury/Trauma/Surgery<br><br>**Reactionary Haemorrhage:** Haemorrhage occurring within first 24 hrs following Trauma/Surgery<br><br>The causes Reactionary Haemorrhage:<br>1) Slipping away of Ligatures<br>2) Dislodgement of Clots<br>3) Cessation of Reflex vasospasm<br>4) Normalization of Blood Pressure<br><br>The precipitating factors are restlessness, coughing and vomiting which raise the venous pressure (e.g. reactionary venous haemorrhage within a few hours of thyroidectomy).<br><br>**Secondary Haemorrhage:** Haemorrhage occurring after 7 -14 days after Trauma/Surgery.<br><br>The attributed cause is infection and sloughing away of the blood vessels.<br><br>The symptoms tell us that the patient is in hypovolemic shock one of the causes of which is haemorrhage and Since here the patient is still in the recovery room this type of haemorrhage is reactionary. |
| **Reference** | |

| | |
|---|---|
| **Q: 209** | A 79 yo lady who is otherwise well recently started abdominal pain. She is |

| | |
|---|---|
| | afebrile and<br>complains that she passed air bubbles during urination. A urethral catheter showed fecal<br>leakage in the urinary bag. What is the likely pathology?<br>a. Diuretics<br>b. CD (fistula more common here)<br>c. Rectosigmoid tumor<br>d. Large bowel perforation<br>e. UC |
| | |
| **Clincher(s)** | |
| A | No history suggestive of diuretic use |
| B | Colovesical fistulae in CD |
| C | • Patient is otherwise well and has no signs and symptoms of rectosigmoidal tumor.. some of which are as follows<br>• Asymptomatic in early stages<br>• Rectal bleeding<br>• Altered bowel habits<br>• Urinary symptoms<br>• Buttock pain<br>• Blood in stool<br>• Black stool<br>• Abdominal pain<br>• Weakness<br>• Weight loss<br>• Loss of appetite |
| D | Symptoms of large bowel perforation may include:<br><br>severe stomach pain<br>chills<br>fever<br>nausea<br>vomiting<br>When peritonitis occurs, the abdomen feels very tender. Pain often worsens when the area is touched or palpated. The abdomen may stick outward farther than normal and feel hard.<br><br>In addition to the general symptoms of perforation, symptoms of peritonitis may include: |

| | |
|---|---|
| | exhaustion<br>passing less urine and/or stools or gas<br>shortness of breath<br>fast heartbeat<br>acute abdomen |
| E | |
| **KEY** | The key is B. CD. [debate came that Crohn's disease cannot occur in 79 yrs but this is not the case! "Crohn's disease can occur at any age, but is most frequently diagnosed in people ages 15 - 35. About 10% of patients are children under age 18". [http://www.nytimes.com/health/guides/disease/crohns-disease/risk-factors.html]. So I think it can occur in this age also and the features support the diagnosis of CD. |

Additional Information

| | Crohn's disease (CD) | Ulcerative colitis (UC) |
|---|---|---|
| **Features** | Diarrhoea usually non-bloody<br>Weight loss more prominent<br>Upper gastrointestinal symptoms, mouth ulcers, perianal disease<br>Abdominal mass palpable in the right iliac fossa | Bloody diarrhoea more common<br>Abdominal pain in the left lower quadrant<br>Tenesmus |
| **Extra-intestinal** | Gallstones are more common secondary to reduced bile acid reabsorption<br><br>Oxalate renal stones* | Primary sclerosing cholangitis more common |
| **Complications** | Obstruction, fistula, colorectal cancer | Risk of colorectal cancer high in UC than CD |
| **Pathology** | Lesions may be seen anywhere from the mouth to anus<br><br>Skip lesions may be present | Inflammation always starts at rectum and never spreads beyond ileocaecal valve<br><br>Continuous disease |
| **Histology** | Inflammation in all layers from mucosa to serosa<br>• increased goblet cells<br>• granulomas | No inflammation beyond submucosa (unless fulminant disease) - inflammatory cell infiltrate in lamina propria<br>• neutrophils migrate through the walls of glands to form crypt abscesses<br>• depletion of goblet cells and mucin from gland epithelium<br>• granulomas are infrequent |
| **Endoscopy** | Deep ulcers, skip lesions - 'cobble-stone' appearance | Widespread ulceration with preservation of adjacent mucosa which has the appearance of polyps ('pseudopolyps') |
| **Radiology** | Small bowel enema<br>• high sensitivity and specificity for examination of the terminal ileum<br>• strictures: 'Kantor's string sign'<br>• proximal bowel dilation<br>• 'rose thorn' ulcers<br>• fistulae | Barium enema<br>• loss of haustrations<br>• superficial ulceration, 'pseudopolyps'<br>• long standing disease: colon is narrow and short -'drainpipe colon' |

## Crohn's disease: investigation

Crohn's disease is a form of inflammatory bowel disease. It commonly affects the term colon but may be seen anywhere from the mouth to anus

Bloods

- C-reactive protein correlates well with disease activity

Endoscopy

- colonoscopy is the investigation of choice
- features suggest of Crohn's include deep ulcers, skip lesions

Histology

- inflammation in all layers from mucosa to serosa
- goblet cells
- granulomas

Small bowel enema

- high sensitivity and specificity for examination of the terminal ileum
- strictures: 'Kantor's string sign'
- proximal bowel dilation
- 'rose thorn' ulcers
- fistulae

| Reference | Crohn's disease: management<br><br>Crohn's disease is a form of inflammatory bowel disease. It commonly affects the term colon but may be seen anywhere from the mouth to anus. NICE published guidelines ( management of Crohn's disease in 2012.<br><br>General points<br>• patients should be strongly advised to stop smoking<br>• some studies suggest an increased risk of relapse secondary to NSAIDs and th contraceptive pill but the evidence is patchy<br><br>Inducing remission<br>• glucocorticoids (oral, topical or intravenous) are generally used to induce remis is an alternative in a subgroup of patients<br>• enteral feeding with an elemental diet may be used in addition to or instead of c induce remission, particularly if there is concern regarding the side-effects of st example in young children)<br>• 5-ASA drugs (e.g. mesalazine) are used second-line to glucocorticoids but are<br>• azathioprine or mercaptopurine* may be used as an add-on medication to indu not used as monotherapy. Methotrexate is an alternative to azathioprine<br>• infliximab is useful in refractory disease and fistulating Crohn's. Patients typicall azathioprine or methotrexate<br>• metronidazole is often used for isolated peri-anal disease<br><br>Maintaining remission<br>• as above, stopping smoking is a priority (remember: smoking makes Crohn's w ulcerative colitis)<br>• azathioprine or mercaptopurine is used first-line to maintain remission<br>• methotrexate is used second-line<br>• 5-ASA drugs (e.g. mesalazine) should be considered if a patient has had previ<br><br>Surgery<br>• around 80% of patients with Crohn's disease will eventually have surgery<br><br>*assess thiopurine methyltransferase (TPMT) activity before offering azathioprine or |
|---|---|

| Q: 323 | A 47yo man comes to the GP with a swelling in his left groin which disappears on lying down.<br>The swelling was bluish in color and felt like a bag of worms. He also complains of a mass in the<br>left loin along with hematuria occasionally. What could be the possible dx? |
|---|---|

| | |
|---|---|
| | a. Left sided RCC<br>b. Varicosity 2nd to liver disease<br>c. Testicular tumor<br>d. UTI<br>e. IVC obstruction |
| | Every patient with varicocoel will need to be ruled out for RCC through US abdomen<br><br>Left Testicular vein one into R RV<br><br>Right testicular vein into IVC |
| **Clincher(s)** | |
| A | |
| B | |
| C | |
| D | |
| E | |
| **KEY** | The key is A. Left sided Renal cell carcinoma |
| Additional Information | Most common secondary cause of left sided varicocele is RCC. Newly diagnosed varicocele over the age of 40yrs are very much suggestive of RCC. Varicocele is common on left side as left testicular veins drain to the left renal vein, while the right testicular vein drain directly into IVC.<br><br>Varicoceole is dilated veins of pampioneform plexus. Left side more commonly affected. Often visible as distended scrotal blood vessels that feel like a 'bag of worms'. Patient may complain of dull ache. Associated with subfertility.<br><br>**Cause[edit]**<br><br>The **idiopathic varicocele** occurs when the valves within the veins along the spermatic cord do not work properly. This is essentially the same process as varicose veins, which are common in the legs. This results in backflow of blood into the pampiniform plexus and causes increased pressures, which on rare occasion can lead to permanent damage to the testicular tissue due to disruption of normal supply of oxygenated blood via the testicular artery.<br><br>Varicoceles develop slowly and may not have any symptoms. They are most frequently diagnosed when a patient is 13–30 years of age, and rarely develop after the age of 40. They occur in 15-20% of all males.<br><br>A majority of idiopathic varicoceles occur on the left side,[13] because the |

left testicular vein travels superiorly and connects to the left renal vein (at a 90-degree angle), while the right testicular vein drains directly into the inferior vena cava. Isolated right sided varicoceles are rare.[citation needed]

A **secondary varicocele** is due to compression of the venous drainage of the testicle. A pelvic or abdominal malignancy is a definite concern when a unilateral right-sided varicocele is newly diagnosed in a patient older than 40 years of age. One non-malignant cause of a secondary varicocele is the so-called "Nutcracker syndrome", a condition in which the superior mesenteric artery compresses the left renal vein, causing increased pressures there to be transmitted retrograde into the left pampiniform plexus.[14] The most common cause is renal cell carcinoma (a.k.a. hypernephroma) followed by retroperitoneal fibrosis or adhesions.

## [Renal cell carcinoma and simultaneous left varicocele].

[Article in Spanish]

Espinosa Bravo R[1], Lemourt Oliva M, Pérez Monzón AF, Puente Guillen M, Navarro Cutiño M, Sandoval López O, de la C Fuentes Milera A.
**Author information**

**Abstract**

**OBJECTIVES:**
To report a rare case of left renal cell carcinoma causing simultaneous acute left varicocele. We also performed a bibliographic review.

**METHODS:**
We present the case of a male adult who was diagnosed as having a left varicocele during a medical exam at his work center and referred to the urology clinic. On physical examination a left flank and hypochondrium mass was found. We analyze the diagnostic tests performed and possible therapies.

**RESULTS:**
With the diagnosis of left hypernephroma the patient underwent surgery. A big lower pole and medial portion kidney tumor displacing neighbor structures was found, and left radical nephrectomy was performed.

**CONCLUSIONS:**
Although it was easy to diagnose a hypernephroma with the diagnostic tests performed, the clinical presentation is not frequent, neither is the sudden onset of left varicocele. Currently, after 8 years of follow-up, the patient has normal blood-ultrasound tests.

PMID:

12918314

[PubMed - indexed for MEDLINE]

| | |
|---|---|
| | |
| **Reference** | http://www.ncbi.nlm.nih.gov/pubmed/12918314<br>OHCM 652, 646<br>wikipedia |

| | |
|---|---|
| **Q: 345** | Pt presented with hemoptysis 7d post-tonsillectomy (infection most common)<br>What is the next step?<br>a. Packing<br>b. Oral antibiotics + discharge<br>c. Admit + IV antibiotics<br>d. Return to theatre and explore<br>e. Ice cream and cold fluids |
| | |
| **Clincher(s)** | |
| A | |
| B | |
| C | |
| D | |
| E | |
| **KEY** | The key is C. Admit + IV antibiotic. [infection is a common cause of secondary haemorrhage, haemoorrhage occurring ]. |
| Additional Information | **Complications of tonsillectomy.**<br>**Primary hemorrhage….less than 24 hours after surgery and often requires a return to theatre.**<br>**Secondary hemmorrage…. Typically after 5-10 days and usually due to infection. Here repeat surgery is rarely needed. It often settles with rest and antibiotics. Friable tissue makes hemostasis difficult and the pillars may need to be sewn together** |
| **Reference** | OHCS 7th edition, page 564. |

| | |
|---|---|
| **Q: 350** | A 28yo shipyard worker was admitted for pain in calf while at work which has been increasing<br>over the last 3m. There is no hx of HTN or DM but he is a smoker. Exam: loss of posterior tibial<br>and dorsalis pedis pulsation along with a non-healing ulcer at the base of the right 1st MTP joint.<br>What is the most probably dx?<br>a. Thromboangitis obliterans<br>b. Sciatica<br>c. DVT |

| | |
|---|---|
| | d. Baker's cyst<br>e. Embolus |
| | |
| **Clincher(s)** | |
| A | Smoking rtelated inflammation of veins, nerves, and middle sized arteries which thrombose and cause gangrene. Cause unknown. Stopping smoking is vital. Most patient are men. |
| B | |
| C | |
| D | **Fluid from knee effusion escapes to form a popliteal cyst which is often swollen and painful, in a gastrocnemius bursa. It may rupture causing compartment syndrome** |
| E | |
| **KEY** | The key is A. Thromboangitis obliterans.<br>Ans. 2. i) young age ii) smoker iii) pain in cuff iv) loss of posterior tibial and dorsalis pedis pulsation v) non-healing ulcer at the base of the right 1st MTP joint all are suggestive of Buerger's disease |
| Additional Information | |
| **Reference** | Ohcm 710 |

| | |
|---|---|
| **Q:484** | 484. A 45yo man underwent an emergency splenectomy following a fall from his bicycle. He smokes 5 cigarettes/day. Post-op, despite mobile, he develops swinging pyrexia and a swollen painful left calf. His CXR shows lung atelectasis and abdominal US demonstrates a small subphrenic collection. What is the single most likely risk factor for DVT in this pt?<br>a. Immobility<br>b. Intraperitoneal hemorrhage<br>c. Smoking<br>d. Splenectomy (hypercoagubility state)<br>e. Sub-phrenic collection |
| | |
| **Clincher(s)** | **Mobile** |
| A | The patient is mobile |
| B | Not related |
| C | Could be a risk but not the most prominent |
| D | **Major surgery and leads thrombocytosis** |
| E | **Not related** |
| **KEY** | **D** |
| Additional Information | KEY- D |

**Splenectomy** (p367) Acute gastric dilatation (a serious consequence of not using a NGT, or to check that the one in place is working); thrombocytosis; sepsis. ►Lifetime sepsis risk is partly preventable with pre-op vaccines—ie *Haemophilus* type B, meningococcal, and pneumococcal (p391 & p160) and prophylactic penicillin. MPH

**Splenectomy** Main indications: splenic trauma, hypersplenism, autoimmune haemolysis: in ITP (p338) or warm autoimmune haemolytic anaemia (p332), congenital haemolytic anaemias. Splenectomy was historically performed for staging in Hodgkin's disease, but CT and MRI have replaced this role. Mobilize early post-splenectomy as transient ↑platelets predisposes to thrombi. A characteristic blood film is seen following splenectomy, with Howell-Jolly bodies, Pappenheimer bodies and target cells (see p322).

►*The main problem post-splenectomy is lifelong increased risk from infection.* The spleen contains macrophages which filter and phagocytose bacteria. Post-splenectomy infection is caused most commonly by encapsulated organisms: *Streptococcus pneumoniae*, *Haemophilus influenzae*, and *Neisseria meningitidis*. Reduce this risk by giving:[128]

1. Immunizations:
   - Pneumococcal vaccine (p160), at least 2 weeks pre-op to ensure good response, or as soon as possible after emergency splenectomy, eg after trauma. Re-immunize every 5-10yrs. Avoid in pregnancy.
   - *Haemophilus influenzae* type b vaccine (Hib, see p391).
   - Meningococcal C vaccine.
   - Annual influenza vaccine (p402).
2. Life-long prophylactic oral antibiotics (phenoxymethylpenicillin). Erythromycin if penicillin allergic.
3. Patient-held cards alerting health professionals to the infection risk.
4. Pendants or bracelets to alert medical staff.
5. Advice to seek medical attention if any signs of infection.
6. Urgent hospital admission if infection develops, for treatment with broad-spectrum antibiotics.
7. If travelling abroad, warn of risk of severe malaria and advise meticulous prophylaxis, with nets, repellent, and medication.

The above advice also applies to hyposplenic patients, eg in sickle-cell anaemia or coeliac disease.

Since it is stated that patient is mobile. option A can be eliminated. Option B and E are not known to predispose to Thromboembolism. This leaves C and D, and splenectomy is a stronger link to DVT due to it being:

1. A recent major surgery(within 12 weeks), which is a big risk factor for DVT.
2. The surgery itself- Vascular events after splenectomy are likely multifactorial, probably resulting from some combination of hypercoagulability, platelet activation, disturbance and activation of the endothelium, and altered lipid profiles. The spleen's primary phagocytic function is to remove infectious organisms, other insoluble cellular debris, and senescent or abnormal red cells and platelets. This

| | |
|---|---|
| | filtration function results from the blood moving slowly through the splenic sinusoids in the red pulp lined with macrophages actively ingesting that which does not easily pass around them. Absence of this extremely sensitive filter may permit particulate matter and damaged cells to persist in the bloodstream, therefore perturbing and activating the vascular endothelium leading to a shift in vascular homeostasis toward enhanced coagulation. |
| **Reference** | OHCM 528 & 367, Rabia |
| Dr Khalid/Rabia | |

| | |
|---|---|
| **Q:514*** ** | 514. Midpoint between the suprasternal notch and pubic symphysis. What is the single most<br>appropriate landmark?<br>a. Fundus of the gallbladder<br>b. Mcburney's point (acute appedic)<br>c. Stellate ganglion<br>d. Deep inguinal ring<br>e. Transpyloric plane (D10 level – know those)<br><br>T8- IVC pierce diaphragm ,<br><br>VOA: V(vena T8 Oeso T10 Aorta T12) |
| | Discussed in Saima's notes |
| **Clincher(s)** | |
| A | At the level of the transpyloric plane (9/10th costal cartilage- tip of scapula)- in cholecystics- due to inflammatory fluid in wall. Normally you can't palpate at 9 CC. |
| B | Mcburney's point is 2 thirds the distance from the umbilicus towards the iliac crest, in which point the appendicectomy incision takes place. |
| C | Stellate ganglion: sympathetic ganglion supplies the face and the arm, located at the level of 6-7 cervical vertebrae (Last cervical vertebra) |
| D | **Deep inguinal ring is located at the mid point of inguinal ligament** |
| E | **The correct answer** |
| **KEY** | **E** |

| | |
|---|---|
| Additional Information | TRANSPYLORIC PLANE<br>(Horizontal line half way between suprasternal notch & pubic symphysis)<br> 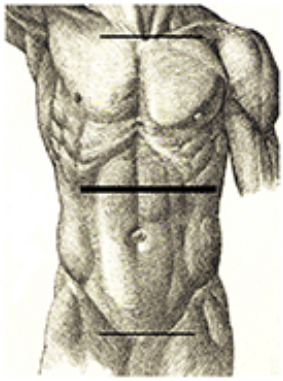 <br> 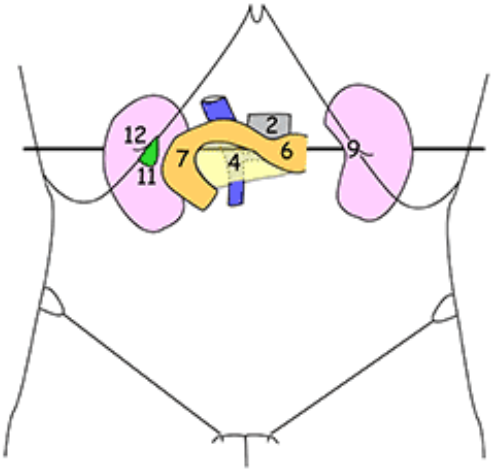 <br><br>Structures approximately on this line:<br>1 End of spinal cord<br>2 L1 vertebral body<br>3 Origin of superior mesenteric art<br>4 Origin of portal vein<br>5 Neck of pancreas<br>6 Pylorus of the stomach<br>7 Second part of duodenum<br>8 Sphincter of Oddi<br>9 Hilum of each kidney<br>10 Duodenojejunal flexure<br>11 Fundus of gall bladder<br>12 Tips of ninth costal cartilages |
| **Reference** | |
| Dr Khalid/Rabia | Rabia, Saima |

| | |
|---|---|
| **Q:515** | 515. Tip of the 9th costal cartilage. What is the single most appropriate landmark?<br>a. Fundus of the gallbladder |

| | |
|---|---|
| | b. Deep inguinal ring<br>c. Termination of the spinal cord<br>d. Transpyloric plane<br>e. Vena cava opening in the diaphragm |
| | |
| **Clincher(s)** | single most appropriate landmark? |
| A | At the transpyloric plane level |
| B | Above the mid point of inguinal ligament |
| C | At L1 or L2 |
| D | **The key** |
| E | **At T8** |
| **KEY** | **D** |
| Additional Information | **Rabia mentioned that it is A but I think this is not correct because it is not a "landmark"** |
| **Reference** | |
| Dr Khalid/Rabia | **Apertures through the diaphragm**<br><br>1. Vena caval hiatus (vena caval foramen)<br>• at the level of T8 and transmits the IVC and occasionally the phrenic nerve.<br>2. Esophageal hiatus<br>• at the level of T10 and transmits the esophagus and vagus nerves.<br>3. Aortic hiatus<br>• at the level of T12 and transmits the aorta, thoracic duct, azygos vein, an occasionally greater splanchnic nerve. |

| | |
|---|---|
| **Q: 524** | 524. Just above the mid-inguinal point. What is the single most appropriate landmark?<br>a. Femoral artery pulse felt<br>b. Mcburney's point<br>c. Stellate ganglion<br>d. Deep inguinal ring<br>e. Transpyloric plane |
| | |
| **Clincher(s)** | |
| A | Femoral artery is felt "at" the mid inguinal point |
| B | 2/3 the way from the umbilicus to the superior iliac crest, incision for the acute appendicitis |
| C | At C7 or C8 |
| D | **key** |
| E | |
| **KEY** | **D** |

| | |
|---|---|
| Additional Information | **At mid inguinal point: we feel the femoral artery.** |
| **Reference** | |
| Dr Khalid/Rabia | |

| | |
|---|---|
| **Q:525** | 525. 5th ICS in the ant axillary line. What is the single most appropriate landmark?<br>a. Apex beat (4th and 5th ICS)<br>b. Chest drain insertion<br>c. Stellate ganglion<br>d. Transpyloric plane<br>e. Vena cava opening into the diaphragm<br><br>drain: 4-6th intercostal triangle can be done- safe triangle |
| | |
| **Clincher(s)** | |
| A | At the 5th ICS in the midclavicular line |
| B | **Chest drain insertion** |
| C | C7 C8 |
| D | |
| E | **T8** |
| **KEY** | |
| Additional Information | |
| **Reference** | |
| Dr Khalid/Rabia | |

| | |
|---|---|
| **Q:1250** | 1250. A 24yo male presents with discomfort in the groin area and scrotal swelling. Exam: scrotal skin is normal. What would be the next best step?<br>a. Urgent US<br>b. Urgent surgery<br>c. OPD referral<br>d. Antibiotics |
| | |
| **Clincher(s)** | |
| A | Not urgent |
| B | **Not urgent** |
| C | |
| D | **No infection** |
| E | |
| **KEY** | **C** |

| | |
|---|---|
| Additional Information | Groin Discomfort and Scrotal Swelling (C)<br>-Discomfort in the groin and scrotal swelling don't indicate an emergency. This rules out urgent ultrasound and urgent surgery.<br>- Since the diagnosis is unclear at this point and there are no signs of infection, antibiotics cannot be prescribed.<br>- The only logical approach would be an OPD referral (C). |
| **Reference** | Rabia |
| Dr Khalid/Rabia | |

| | |
|---|---|
| **Q:250** | A 28yo shipyard worker (not stationary) was admitted for pain in calf while at work which has been increasing over the last 3m. There is no hx of HTN or DM but he is a smoker. Exam: loss of posterior tibial and dorsalis pedis pulsation along with a non-healing ulcer at the base of the right 1st MCP joint. What is the most probably dx? |
| | |
| **Clincher(s)** | no hx of HTN or DM, smoker, loss of posterior tibial and dorsalis pedis pulsation, non-healing ulcer, man, 28yrs old |
| A | Thromboangitis obliterans |
| B | Sciatica |
| C | DVT |
| D | Embolus |
| E | Baker's cyst |
| **KEY** | **Thromboangitis obliterans** |
| Additional Information | **Buerger' s disease (thromboangiitis obliterans) Non-atherosclerotic smoking-related infl ammation and thrombosis of veins and middle-sized arteries causing thrombophlebitis and ischaemia (ulcers, gangrene).** *Cause:* **Unknown. Stopping smoking is vital. Most patients are men aged 20-45yrs** |
| **Reference** | OHCM pg 710 |

| | |
|---|---|
| **Q:358** | A 35yo construction worker is dx with indirect inguinal hernia. Which statement below best describes it? |
| | |
| **Clincher(s)** | indirect inguinal hernia |
| A | Passes through the superficial inguinal ring only |
| B | Lies above and lateral to the pubic tubercle |
| C | Does not pass through the superficial inguinal ring |
| D | Passes through the deep inguinal ring |
| E | |
| **KEY** | Passes through the deep inguinal ring |
| Additional Information | **Definition of a hernia** The abnormal protrusion of a viscus or part of a viscus through a weakness in its containing wall. An indirect inguinal hernia results from the failure of |

| | |
|---|---|
| | embryonic closure of the deep inguinal ring after the testicle has passed through it.<br>Direct Indirect<br> 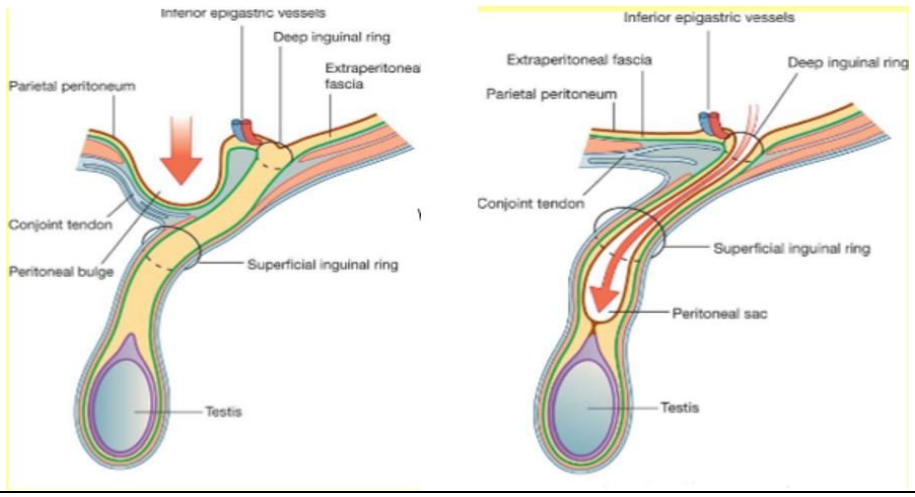 |
| **Reference** | |

| | |
|---|---|
| **Q:361** | A 55yo man has been admitted for elective herniorraphy. Which among the following can be the reason to delay his surgery? |
| | |
| **Clincher(s)** | |
| A | Controlled asthma |
| B | Controlled atrial fib |
| C | DVT 2yrs ago |
| D | Diastolic BP 90mmHg |
| E | MI 2 months ago |
| **KEY** | **MI 2 months ago** |
| Additional Information | Non-urgent surgery should be delayed for at least 6 months following acute MI and, possibly, acute ischaemia. Cancer surgery may be undertaken if the risk of disease progression is felt to outweigh the increased perioperative mortality rate. Continue antiplatelet medication if not contraindicated.<br>In patients with a previous MI, this is a 50-fold increase over the risk in patients who have never had an MI. |
| **Reference** | OHCS: Page 54, Open Anesthesia Research paper |

| | |
|---|---|
| **Q:364** | A 22yo sexually active male came with 2d hx of fever with pain in scrotal area. Exam: scrotal skin is red and tender. What is the most appropriate dx? |
| | |
| **Clincher(s)** | 22yo, sexually active, 2d hx, fever, scrotal skin is red and tender. |
| A | Torsion of testis |
| B | Orchitis (testis- more common in kids and with mumps- parotid/testis – same |

| | |
|---|---|
| | agent- mums leads to orchitis and - infertility) |
| C | Inguinal hernia |
| D | Epididymo-orchitis (inflammation of epi and testis- in STI through urethra- infection ascend- goes to epidemidymis) |
| E | |
| **KEY** | Epididymo-orchitis |
| Additional Information | Torsion of Testes: Peak age of incidence 12–18y. Sudden onset of moderate to severe, constant, unilateral scrotal pain, often with nausea, vomiting, and abdominal pain.May have been preceding episodes of intermittent pain that suddenly resolved. The testis is globally tender, high in the scrotum, may have a transverse axis, and be slightly enlarged. If it is infarcted, scrotal wall oedema and tenderness may be present. Absence of ipsilateral cremasteric reflex is the most reliable sign.<br><br>Epididymo-orchitis : Peak incidences vary according to cause, ages 35y and >55y. Common organisms include *Chlamydia trachomatis*, *Neisseria gonorrhoea* in the young (sexually-transmitted infections (STI)). *Escherichia coli* and *Proteus* occur in chronic bladder outfl ow<br>obstruction or urinary tract instrumentation. One-third of male adolescents with mumps develop orchitis, which is unilateral in 80%; a third of these testes atrophy.<br>Gradual onset of pain (hours or days). Dysuria, urethral discharge, and pyrexia are common. Tenderness and induration are localized to the epididymis and spermatic cord in epididymitis. Cremasteric reflex is preserved. Prehn's sign (relief of pain with scrotal elevation).<br> 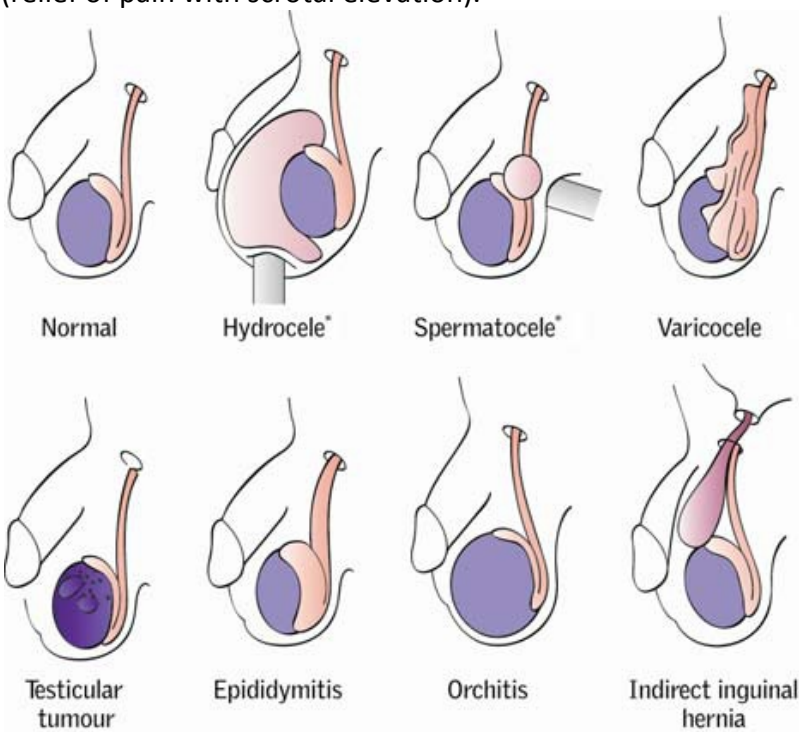 <br> |
| **Reference** | OHCS |

| **Q:365** | A man on warfarin posted for hemicolectomy. As the pt is about to undergo surgery. What option is the best for him? |
|---|---|
| | |
| **Clincher(s)** | |
| A | Continue with warfarin |
| B | Continue with warfarin and add heparin |
| C | DVT 2yrs ago Stop warfarin and add aspirin |
| D | Stop warfarin and add heparin |
| E | Stop warfarin |
| **KEY** | **Stop warfarin and add heparin** |
| Additional Information | *Minor surgery* can be undertaken without stopping *warfarin* (if INR <3.5 it may be safe to proceed). In *major surgery*, drugs may be stopped for 2–5d pre-op. Risks and benefits are individual to each patient, so exact rules are impossible. Discuss these issues when arranging consent. *Vitamin K* FFP or *Beriplex*R may be needed for emergency reversal of INR. One elective options conversion to *heparin* (stop 6h prior to surgery, and monitor APTT perioperatively): unfractionated heparin's short *t*. allows swift reversal with *protamine.* When re-warfarinizing, continue heparin until the INR is therapeutic, as warfarin is prothrombotic in the early stages. |
| **Reference** | OHCM pg 592 |

| **Q: 1078** | Pt with pain and swelling in left leg and thigh up to the level of inguinal ligament. Where is the level of occlusion? Read compartment syndrome<br>a. Femoro-popliteal artery (swelling should be below knee joint)<br>b. Left common iliac artery<br>c. Aortoiliac artery<br>d. Femoral artery (collat circulation around neck of femur)<br>e. Profound femoral artery |
|---|---|
| | |
| **Clincher(s)** | pain and swelling in left leg and thigh **up to the level of inguinal ligament** |
| A | Femoral artery becomes popliteal artery behind the knee.<br>femoro-popliteal obstruction:<br>• unilateral claudication in calf<br>• femoral pulses palpable with absent unilateral distal pulses |
| B | |
| C | Aortoiliac occlusion also known as leriche's syndrome;<br>• claudication in both buttocks, thighs and calves<br>• femoral and distal pulses absent in both limbs<br>• impotence<br>• bruit over aorto-iliac region |
| D | |
| E | |
| **KEY: B** | **Left common Iliac artery** |

- If an artery higher upstream is narrowed, such as the iliac artery or aorta, then you may develop pain in your thighs or buttocks when you walk. (patientinfo)
- External iliac artery becomes femoral artery when it passes under the inguinal ligament.
- iliac obstruction S/S: (GP notebook )
  - ~ unilateral claudication in thigh and calf, sometimes buttock
  - ~ bruit over iliac region
  - ~ unilateral absence of femoral and distal pulses

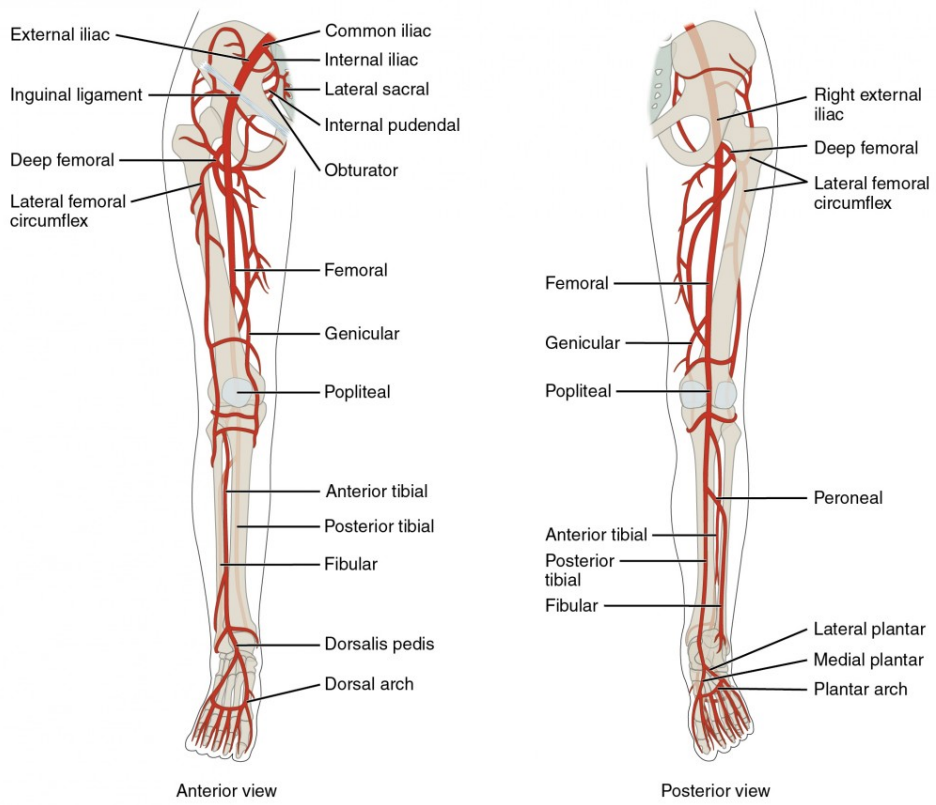


The location of the pain in patients with peripheral arterial occlusive disease (PAOD) is determined by the anatomic location of the arterial lesions. PAOD is most common in the distal superficial femoral artery (located just above the knee joint), a location that corresponds to claudication in the calf muscle area (the muscle group just distal to the arterial disease). When atherosclerosis is distributed throughout the aortoiliac area, thigh and buttock muscle claudication predominates.

**Risk factors:** Smoking, Diabetes mellitus. Hypertension. Hyperlipidaemia: high total cholesterol and low high-density lipoprotein (HDL) cholesterol are independent risk factors. Physical inactivity. Obesity.

The most **common symptom** is muscle pain in the lower limbs on exercise (intermittent claudication):

| | |
|---|---|
| | * Walking impairment - eg, fatigue, aching, cramping or pain in the buttock, thigh, calf or foot, particularly when symptoms are quickly relieved at rest. Pain comes on more rapidly when walking uphill than on the flat. Claudication can occur in both legs but is often worse in one leg.<br>* The **differential diagnosis** of pain in the lower limb when walking includes sciatica and spinal stenosis, deep vein thrombosis, entrapment syndromes and muscle/tendon injury.<br>* The main method to **confirm the diagnosis** is Doppler ultrasonography (duplex scanning). The ratio of systolic blood pressure at the ankle and in the arm - ankle-brachial pressure index (ABPI) - provides a measure of blood flow at the level of the ankle (as a general guide, normal = 1, claudication 0.6-0.9, rest pain 0.3-0.6, impending gangrene 0.3 or less). The ABPI is a strong marker of cardiovascular disease and is predictive of cardiovascular events and mortality<br>* **Treatment** includes reduction and modification of risk factors, medical management with anti- platelets and peripheral vasodilators. Surgical procedures such as endovascular revascularization and bypass surgery. |
| Additional Information | **Why not femoral artery?** |
| **Reference** | |

| | |
|---|---|
| **Q: 1097** | A 55yo male has been admitted for elective herniorrhaphy. Which among the following can be the reason to delay his surgery?<br>a. Controlled asthma<br>b. Controlled A-fib<br>c. DVT 2yrs ago<br>d. DBP 90 mmHg<br>e. MI 2m ago |
| | |
| **Clincher(s)** | |
| A, B, C | No contraindications |
| D | |
| E | |
| **KEY: E** | Dr. Rabia>> MI 2 months ago seems appropriate but new guidelines suggest even a period of two months after MI is enough. Otherwise at least a period of 3 months is needed. |
| Additional Information | FB discussion:<br>"Any MI in the last 6months or less, is an absolute contraindication to surgery.<br>Hypotension is NOT an absolute contraindication to surgery.<br>Remember ruptured ectopic, u still do a laparotomy even if BP is low" |
| **Reference** | |
| | |
| | |

| | |
|---|---|
| **Q:1100** | A 17yo girl with a lump in her breast was seen in the clinic. Exam: the lump was free and mobile and not attached to the skin. Her mother wants further tests done. What should be the next step?<br>a. CT<br>b. US breast<br>c. Punch biopsy<br>d. Reassure and send home<br>e. Stereotactic biopsy |
| | |
| **Clincher(s)** | 17yo girl, lump was **free and mobile and not attached** to the skin. |
| A | |
| B | |
| C | |
| D | |
| E | |
| **KEY: B** | **US**<br>**Benign breast disease**[91]<br>*Fibroadenoma:* Usually presents <30yrs but can occur up to menopause. Benign overgrowth of collagenous mesenchyme of one breast lobule. Firm, smooth, mobile lump. Painless. May be multiple. ⅓ regress, ⅓ stay the same, ⅓ get bigger. ℞: Observation and reassurance, but if in doubt refer for USS (usually conclusive) ± FNA. Surgical excision if large. |
| Additional Information | Triple assesment for breast lump<br>• clinical examination<br>• imaging :mamography if older than 35 years or u/s for younger patients<br>• FNAC<br><br>**<u>Fibroadenoma</u>**<br><br>This is a benign tumour that is common in young women, mostly aged under 40 years. They are the most common tumour of the breast in those under 30 years old, but overall they are second to breast cancer. Assessment often includes examination, imaging studies and fine-needle aspiration. Ultrasound >>> in younger women with dense breasts, as mammograms are more difficult to interpret in this group. Routine mammography, as a population screening tool, is not performed below the age of 50 years.<br><br>• The initial examination depends upon the age of the patient. Ultrasound for <35 years old; Mammography and then Ultrasound for >35 years old.<br>• Ultrasound is best for dense breast tissue, whereas Mammography is best for less dense breast tissue; eg, after menopause. |

| | |
|---|---|
| | • CT is not done for breast lesions.<br>• Stereotactic Biopsy is the investigation of choice only when there are no palpable masses. |
| **Reference** | |

| | |
|---|---|
| **Q:1104** | A 25yo woman presents with a single lump in the breast and axilla. The lump is mobile and hard in consistency. The US, mammogram and FNA (fine-needle aspiration) turn out to be normal. What is the most appropriate inv to confirm the dx?<br>a. FNAC (fine needle aspiration cytology)<br>b. MRI<br>c. Punch biopsy<br>d. Genetic testing and counselling<br>e. Core biopsy |
| | |
| **Clincher(s)** | |
| A | |
| B | |
| C | |
| D | |
| E | |
| **KEY: E** | **Core Biopsy**<br> 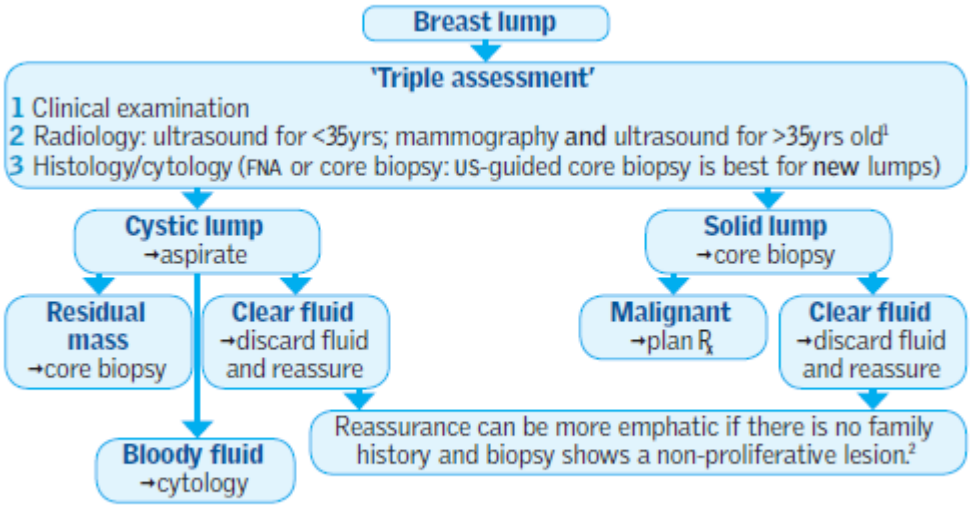 <br><br>Fig 1. Triple assessment and investigation of a breast lump.<br><br>**Dr. Rabia >>** in palpable mass we do triple assessment : clinical examination,imaging,FNAC >>>if not conclusive we do core biopsy then excional biopsy if still non conclusive<br>Breast lump triple assessment |

| | |
|---|---|
| | • Examination<br>• imaging: mamogaraphy,u/s<br>• biopsy<br>>> non palpable lesion:<br>1. core biopsy(image -guided)<br>2. open biopsy(needle localisation >>> radio opaque needles are used to guide the boipsy0<br>>>palpable lesion:<br>1. FNAC<br>2. core biopsy<br>3. excision biopsy (entire lesion is removed)<br>4. incision biopsy (part of the lesion) |
| Additional Information | |
| **Reference** | OHCM pg: 605 |

| | |
|---|---|
| **Q:1106** | A lady with a firm smooth breast lump in outer quadrant had a FNAC done. Results showed borderline benign changes. She also has a fam hx of breast cancer. What is the your next?<br>a. Mammography<br>b. US<br>c. Core biopsy<br>d. Genetic testing and counselling<br>e. Punch biopsy |
| | |
| **Clincher(s)** | |
| A | |
| B | |
| C | |
| D | |
| E | |
| **KEY: D** | **Genetic testing and counselling**<br>reason: assessment of the case is complete (borderline benign change) → next step is genetic testing and counselling.<br>breast lump >>>discussed earlier<br>In this question a lady underwent an FNAC and the results have showed benign breast changes. She also has a risk for developing breast cancer because of her family history. All options but one is investigation, which we don't need at this point because we got all we could get from the investigations. What needs to be done now is to assess the risk of breast cancer in this patient. Also, the patient needs to be counselled about the disease. Therefore, we should for genetic testing and counselling. |
| Additional Information | |

| Reference | |
|---|---|

| Q: 1152 | . A pt comes with 6m hx of painless bilateral swelling of the face which has been progressively<br><br>increasing in size. On routine CXR, he is found to have perihilar lymphadenopathy. What is the<br><br>most probable dx?<br><br>a. Chronic sialadenitis<br><br>b. Thyroid adenoma<br><br>c. Carcinoma of salivary gland<br><br>d. Adenoid cystic carcinoma<br><br>e. Mikulicz's disease |
|---|---|
| | |
| **Clincher(s)** | **6m , painless bilateral swelling of face , perihilar lymph adenopathy** |
| A | ChronicSialadenitis-refers to inflammation of a salivary gland and may be acute or chronic, infective or autoimmune in parotid ,sub-mandibular and lingual gland,80% pathology occurs in parotid |
| B | Thyroid adenoma-swelling loacted over neck<br>*Chronic bilateral symptoms* may coexist with dry eyes and mouth and autoimmune disease,eg hypothyroidism, Mikulicz's or Sjogren's |
| C | Carcinoma of salivary gland-*Carcinomas:* Rapid growth; hard fi xed mass; pain &VIIthnerve palsy.Surgery<br>+ radiotherapy. PET scan is better than CT and MRI for staging, detecting<br>local recurrence and regional lymph node and distant metastases. |
| D | Adenoid cystic carcinoma-*:* Rare tumour of exocrine mucous glands (salivary, lacrimal, lid).slow growing mass+ late recurrences + perineural in fi ltration+ distant<br>mets. Survival: 88%, 69% and 52% at 5, 10 and 15yrs. Follow-up:for life.<br><br>**From ohcs** |
| E | • Mikulicz'sdisease( variant of sjogrensynd)-Symmetric , persistent swelling of lacrimal and parotid gland. (By exclusion)<br>• It is diagnosed when -Sarcoidosis (note, Heerfordt's syndrome = sarcoidosis with parotid enlargement, fever,anterior uveitis, and facial nerve palsy). And others such as ,viral infection, tb, sjogren syndrome , lymphoproliferative disorders are excluded |

| | **Pg-720 ohcm**<br>**http://patient.info/doctor/salivary-gland-disorders** |
|---|---|
| **Key** | Mikulicz's Disease (E) - Bilateral parotid and lacrimal gland enlargement was characterized by the term Mikulicz's disease, |
| Additional Information | - salivary gland tumors-'80% are in the parotid, 80% of these are pleomorphicadenomas, 80% of these are in the superficial lobe.' Deflection of the ear outwards isa classic sign. Remove any salivary gland swelling for assessment if present for >1month. VIIth nerve palsy means malignancy<br><br>*Acute swelling* Think of mumps and HIV<br>. *Recurrentunilateral pain and swelling* is likelyto be from a stone. 80% are submandibular<br>*Chronicbilateral symptoms* may coexist with dryeyes and mouth and autoimmune disease,eg hypothyroidism, Mikulicz's or Sjogren'ssyndrome (p720 & p724)—also bulimia. *Fixedswelling* may be from a tumour/ALL .sarcoid, amyloid, Wegener'ssyndrome,or be idiopathic.(pg 617 ohcm 9th ed)<br><br>**causes of salivary gland swelling ( patient.info.uk)**<br>In the parotid glands, these include:<br><br>• . Viral parotitis - mumps (bilateral in 90%).[1]<br>• Stone in salivary duct.<br>• Benign and malignant tumours.<br>• Sjögren's syndrome.<br>• Sarcoidosis (note, Heerfordt's syndrome = sarcoidosis with parotid enlargement, fever,anterior uveitis, and facial nerve palsy).<br>• Acute and chronic bacterial parotitis.<br>• Wegener's granulomatosis.<br>• HIV-related lymphocytic infiltration<br><br>In the submandibular glands:<br>Stone in the salivary duct<br>Benign and malignant tumours.<br>Sjögren's syndrome (less common).<br><br>In the minor salivary glands:<br>Mucoceles.<br>Benign and malignant tumours. |

| | |
|---|---|
| | - Treatment usually consists of observation unless the patient has concern, there is pain, drainage, or other symptoms related to the lesion. Surgical removal of the affected gland would be recommended in those cases.<br><br>"In **Mikulicz syndrome*** there is enlargement of the parotid and lacrimal glands due to sarcoidosis, tuberculosis or lymphoma<br><br>*this term is now considered outdated and unhelpful by many as there is a confusing overlap with Sjogren's syndrome" Passmedicine |
| **Reference** | http://patient.info/doctor/salivary-gland-disorders<br>ohcm 9th edpg 617 |

| | |
|---|---|
| **Q:1159** | A 28yo female presented with complains of difficulties in swallowing liquids only. She alsosuffers from recurrent chest infection in the past few months. What is the most probable dx?<br><br>a. Foreign body<br><br>b. Plummer vinson syndrome<br><br>c. Achalasia cardia<br><br>d. Peptic stricture<br><br>e. Esophageal carcinoma |
| | |
| **Clincher(s)** | **28 Female , diff in swallowing liquid , recurrent chest infect** |
| A | Foreign body |
| B | Plummer vinson syndrome (eso webs- due to Iron def anemia) |
| C | Achlasiacardia |
| D | **Peptic stricture** |
| E | **Esophageal ca** |
| **KEY** | key : c<br><br>reason : liquid dysphagia + recurrent chest infection ( due to regurgitation)<br><br>Achalasia is a motility disorder of the lower oesophageal or cardiac sphincter. The smooth muscle layer of the oesophagus has impaired peristalsis and failure of the sphincter to relax causes a functional stenosis |

| | |
|---|---|
| Additional Information | https://en.wikipedia.org/wiki/Esophageal_dysphagia<br>*Main article: esophageal web*<br>***Achalasia*** is an idiopathic motility disorder characterized by failure of lower esophageal sphincter (LES) relaxation as well as loss of peristalsis in the distal esophagus, which is mostly smooth muscle. Both of these features impair the ability of the esophagus to empty contents into the stomach. Patients usually complain of dysphagia to both solids and liquids. Dysphagia to liquids, in particular, is a characteristic of achalasia. Other symptoms of achalasia include regurgitation, night coughing, chest pain, weight loss, and heartburn. The combination of achalasia, adrenal insufficiency, and alacrima (lack of tear production) in children is known as the triple A (Allgrove) syndrome. In most cases the cause is unknown (idiopathic), but in some regions of the world, achalasia can also be caused by Chagas disease due to infection by *Trypanosoma cruzi*.<br>*Main article: achalasia*<br><br>presentation :<br>• The most common presenting feature is dysphagia. This affects solids more than soft food or liquids.<br>• Regurgitation , Chest pain , Heartburn ,<br>• Nocturnal cough and even inhalation of refluxed contents >> recurrent chest infection<br><br>Investigations :<br><br>Manometry is the gold standard for diagnosis of achalasia.<br>• CXR : The classical picture of a CXR in achalasia shows a vastly dilated oesophagus behind the heart<br>• Barium swallow : the bird beak appearance<br>• Endoscopy : can detect approximately a third of achalasia<br>• loweoesophogeal PH monitoring >> to exclude GERD<br><br>MANAGEMENT :<br>• the Heller myotomy is the best treatment for those who are fit<br>• Pneumatic dilatation is the preferred option for older unfit patients<br>• Calcium-channel blockers and nitrates may be used for those who are unable to tolerate other forms of treatment<br>• Endoscopic injection of botulinum toxin >>> recurrence |
| **Reference** | Ohcm |

| | |
|---|---|
| **Q:1167** | A pt presented with **jaundice, fever and upper abdominal pain** (Sharcoid(?) triad: characteristic of acute cholangitis) within 24h after removal ofgallstone by ERCP. The cholangiography was done and it (CBD) was patent (but not above due to this). What is the possible cause<br><br>of his complaints? |

| | |
|---|---|
| | a. Biliary infection<br><br>b. Acute pancreatitis<br><br>c. Perforation<br><br>. |
| | |
| **Clincher(s)** | **Fever , jaundice , upper abd pain , post ercp status** |
| A | Biliary infection |
| B | Acute pancreatitis |
| C | Perforation |
| D | **Xx** |
| E | **Xx** |
| **KEY** | key : b<br><br>cause : post ERCP pancreatitis |
| Additional Information | • ERCP Complications<br>• Pancreatitis - 2-9% of patients will develop pancreatitis , perioperative indomethacin or diclofenac reduce the incidence of pancreatitis.<br>• cholangitis<br>• Bleeding may occur<br><br>Perforation of the duodenum with development of an acute abdomen<br>• Mortality 0.2% over all<br>• 0.4% if trying to remove stone |
| **Reference** | |

| | |
|---|---|
| **Q:1493** | An 88yo woman is a known smoker. She had an attack of MI 2y back and is known to have peripheral vascular disease. She presents with an irreducible herniation over the incision region of a surgery which she underwent in her childhood. What is the most appropriate tx?<br>a. Truss<br>b. Elective herniorrhaphy<br>c. Urgent herniorrhaphy<br>d. Elective herniotomy<br>e. Reassure |
| | |
| **Clincher(s)** | **88yr , smoker , MI , vascular disease. Irreducible hernia over incision** |
| A | Truss- may be used when operation is contraindicated orrefused , the hernia must be reducible. increases the risk of strangulation if not fit properly |
| B | Elective herniorraphy- |

| | |
|---|---|
| C | Urgent herniorraphy |
| D | Elective herniotomy- it entails dissecting<br>out and opening the hernial sac, reducing any contents and then transfixing the neck of the sac and removing the remainder.<br>It is employed either by itself or as the first step in a repair procedure (herniorrhaphy).<br>By itself it is sufficient for the treatment of<br>hernia in infants, adolescents and young adults |
| E | Reassure.- Nevertheless, most cases of incisional hernia are asymptomatic<br>and broad-necked and do not need treatment. |
| **KEY** | Answer= B. Elective herniorrhaphy. |
| Additional Information | Burst abdomen In 1–2% of cases, mostly between the sixth and eighth day after operation, an abdominal wound bursts open and viscera are extruded.surgery urgently reqd<br>. An incisional hernia usually starts as a symptomless partial disruption of the deeper layers during the immediate or early postoperative period, the event passing unnoticed if the skin wound remains intact after the skin sutures have been removed<br>**the case is incisional hernia**<br>Factors<br>-Midline and vertical incisions have a greater tendency to burst than those that are transverse.<br>- Deep wound infection<br>- Coughing, vomiting and distension<br>- Overvigorous postoperative ventilation in sedated patients can lead to wound disruption.<br>-General condition of the patient : Obesity, jaundice, malignant disease, hypoproteinaemia and anaemia are all factors conducive to disruption of a laparotomy wound. Abdominal wounds in pregnancy are notorious.<br>variations<br>-The hernia may occur through a small portion of the scar, often the lower end.<br>-More frequently there is a diffuse bulging of the whole length of the incision.<br>A postoperative hernia, especially one through a lower abdominal scar, usually increases steadily in size and more and more of its contents become irreducible .Sometimes the skin overlying it is so thin and atrophic that normal peristalsis can be seen in the underlying intestine. Attacks of partial intestinal obstruction are common and strangulation is liable to occur at the neck of a small sac or in a loculus of a large one. Nevertheless, most cases of incisional hernia are asymptomatic and broad-necked and do not need treatment.Pg 1007 Bailey love – 25th ed<br><br>**Incisional hernias**<br>■Rarely strangulate<br>■Large ones may be dangerous to reduce<br><br>**Management**<br><br>Palliative<br>An abdominal belt is sometimes satisfactory, especially in cases of a hernia through an upper abdominal incision.<br>Operation<br>To attempt to reduce very large hernia to the main abdominal cavity if they have not been there for |

| | |
|---|---|
| | several years is to court danger, particularly if weight reduction has not been effected. In these circumstances there is not only a risk of failure of the hernioplasty but also a greatly increased risk of paralytic ileus from visceral compression and of pulmonary complications from elevation of the diaphragm<br>***Plastic fibre mesh or net closures*** These techniques are now the method of choice for all but the smallest defects (< 4 cm). A sheet of polypropylene mesh is then inserted between the posterior rectus sheath and the muscle fibres and anchored in place.<br>***Simple apposition***The hernial sac is dissected, then opened and the contents are reduced. Adherent omentum and bowel have to be freed by dissection.The layers are repaired, usually with non-absorbale sutures. first the peritoneum and then the fascial (aponeurotic) layers. The muscles and the remaining fascial layer are approximated. Tension-relaxing incisions may be required and should be placed well laterally<br>***Complex apposition obsolete*** |
| **Reference** | Bailey and love edt 25th – page 1007 |

| | |
|---|---|
| **Q:1509** | 1509. A 70yo pt comes with swelling in the parotid region for the last 10y. Exam: gland is soft and cystic. Choose the most probable dx?<br>a. Pleomorphic adenoma<br>b. Carcinoma of the salivary glands<br>c. Mikulicz's disease<br>d. Adenoid cystic carcinoma??<br>e. Parotid duct stones |
| | |
| **Clincher(s)** | **70 yr , swelling in parotid ,10yr history – examination findings** |
| A | Pleomorphic adenoma-often present in middle age and grow slowly. Remove by superficialparotidectomy(excision of parotid above fascial nerve ): firm and hard.<br>- salivary gland tumors-'80% are in the parotid, 80% of these are pleomorphicadenomas, 80% of these are in the superficial lobe.' Deflection of the ear outwards isa classic sign. Remove any salivary gland swelling for assessment if present for >1month. VIIth nerve palsy means malignancy |
| B | Carcinoma of salivary gland-- Carcinomas: rapid growth; hard fixed mass; pain; facial palsy. Treatment: surgery + radiotherapy |
| C | Mikulickz disease- symmetric swelling |
| D | 1)Adenoid cystic carcinoma ???-Rare tumour of exocrine mucous glands (salivary, lacrimal,lid). slow growing mass+ late recurrences + perineural infiltration + distant mets. Survival: 88%, 69% and 52% at 5, 10 and 15yrs. (patient.info)<br><br>*Adenoid cystic carcinoma from ohcspg 269*<br>• A slow growing malignant tumour with indolent behaviour.<br>• Perineural invasion propensity and facial palsy common with extension through stylomastoid foramen. Lung metastasis common.<br>• Often regarded as incurable, but individuals can lead a normal life over 20–30y before succumbing.<br>• Treatment is extensive wide local excision, with nerve/organ preservation where possible. Post-operative radiotherapy has a role. Radiotherapy also has a role in controlling lung symptoms if they arise.<br><br>2) Cystadenolymphomas (Warthin's tumour): usually oldermen; soft; treat by |

| | |
|---|---|
| | enucleation. |
| E | **Parotid duct stone- recurrent , red, tender on exam** |
| **KEY** | Answer: D ??? I THINK ANSWER IS **CYSTADENOLYMPHOMA** (skype: correct)<br>Adenoid cystic carcinoma (ACC) is an uncommon and unusually indolent cancer arising within glands and occurring mainly in the head and neck..It can present as a painless slow-growing mass in the face or mouth. |
| Additional Information | Pleomorphic adenomas often present in middle age and grow slowly. Remove |
| **Reference** | **Pg-617ohcm9TH ED**<br>**http://patient.info/doctor/salivary-gland-disorders** |

| BENINGN OR MALIGNANT | MALIGNANT | MALIGNANT |
|---|---|---|
| CystadenolymphomaMucoepidermoid | | Squamous or adeno ca |
| Pleomorphic adenoma | Acinic cell | Adenoid cystic ca |

8. A man undergoes a pneumonectomy. After surgery, invs show hyponatremia. What could be the
cause of the biochemical change?
a. Removal of hormonally active tumor
b. Excess dextrose
c. Excess colloid
d. Excessive K+
e. Hemodilution

44. A 50yo pt is admitted for elective herniorraphy. Which of the following options will lead to a
postponement of the operation?
a. SBP <90mmHg
b. MI 2 months ago
c. Hgb 12g/dl
d. Pain around hernia
e. Abdominal distention

155. A 15yo boy has a soft painless swelling in the left scrotum, blue in color and can be compressed.
What is the most appropriate next step?
a. Analgesia
b. Antibiotic
c. Biopsy
d. Immediate surgery
e. Reassurance (varicocele- self resolving in kids)- even in adults no symptoms- reassure

160. A 30yo woman has brief episodes of severe shooting pain in the rectum. Rectal examination and
flexible sigmoidoscopy are normal. What is the most probable dx?
a. Anal hematoma
b. Anal fissure
c. Rectal carcinoma
d. Proctalgia fugax (false pain due to spasm- drug- amytriplyline- gaba for diabetic neurophathy – and panthom limb)
e. Piles

161. A 78yo male, DM and HTN, had a fall and since then is unable to walk. He presents with deformity and tenderness over the right hip area. XR=fx of femur neck. What is the single most associated nerve injury?
a. Sciatic nerve
b. Gluteal nerve
c. Lateral peroneal nerve
d. Tibial nerve
e. Femoral nerve

188. A man presents with scrotal swelling, the swelling is cystic and is non-tender. It is located in the
upper pole of the posterior part of the testis. What is the most likely dx?
a. Epididymal cyst
b. Testicular ca
c. Hydrocele
d. Teratoma
e. Testicular torsion

191. A 37yo female had a fall with outstretched hand, presented with dinner fork deformity and
tenderness over the right arm. What is the single most associated nerve injury?
a. Axillary nerve
b. Radial nerve
c. Musculocutaneous nerve
d. Median nerve
e. Ulnar nerve